



JOHANNES GUTENBERG  
UNIVERSITÄT MAINZ

UNIVERSITÄTS**medizin.**

MAINZ

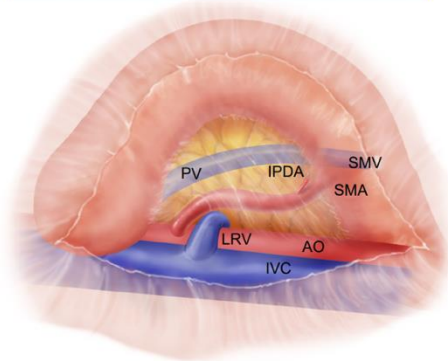
**Pancreatic ductal adenocarcinoma**

**The perfect pancreatoduodenectomy**

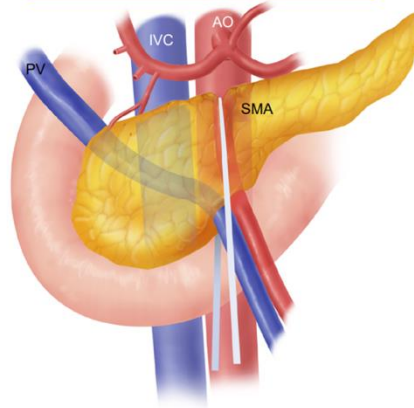
Orlando Jorge Martins Torres  
Department of Gastrointestinal Surgery  
Hepatopancreatobiliary Unit  
Maranhão Federal University - Brazil

# ARTERY FIRST APPROACH

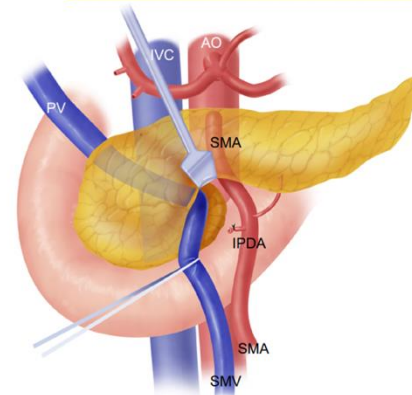
## RIGHT POSTERIOR APPROACH



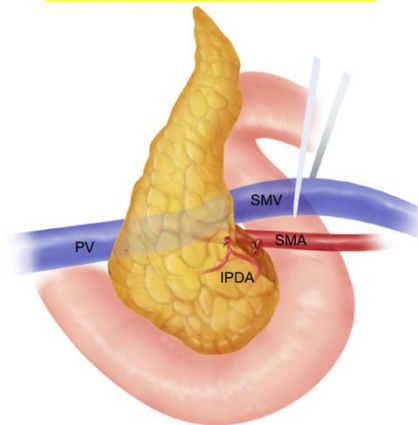
## SUPERIOR APPROACH



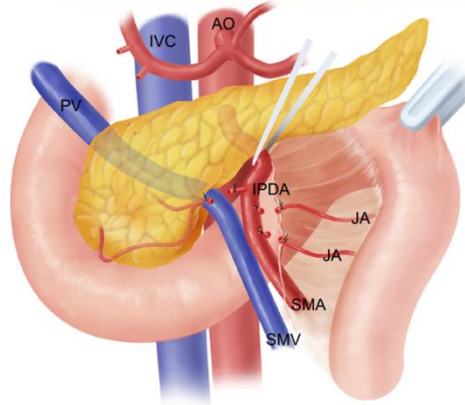
## ANTERIOR APPROACH



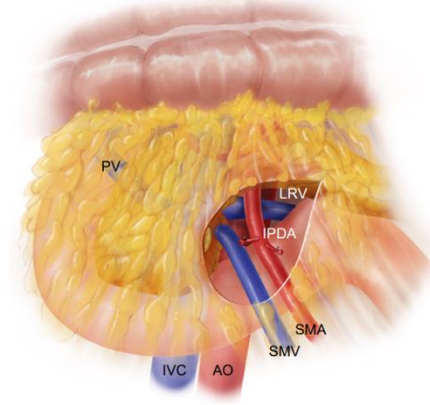
## UNCINATE APPROACH



## LEFT POSTERIOR APPROACH




## MESENTERIC APPROACH



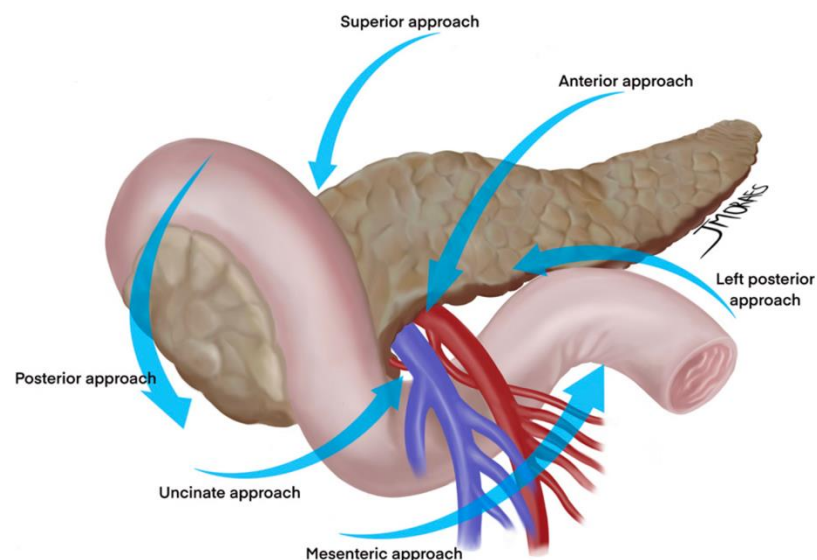


## What do surgeons need to know about the mesopancreas

Eduardo de Souza M. Fernandes<sup>1,2</sup> · Oliver Strobel<sup>3,4</sup> · Camila Girão<sup>1,2</sup> · Jose Maria A. Moraes-Junior<sup>5,6</sup> · Orlando Jorge M. Torres<sup>5,6</sup> 

**Table 3** Advantages of the artery-first approach (SHARMA) [35]

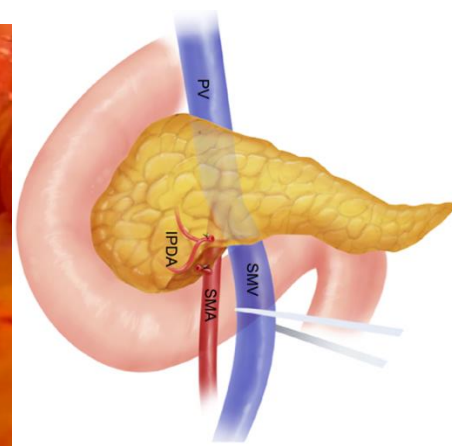
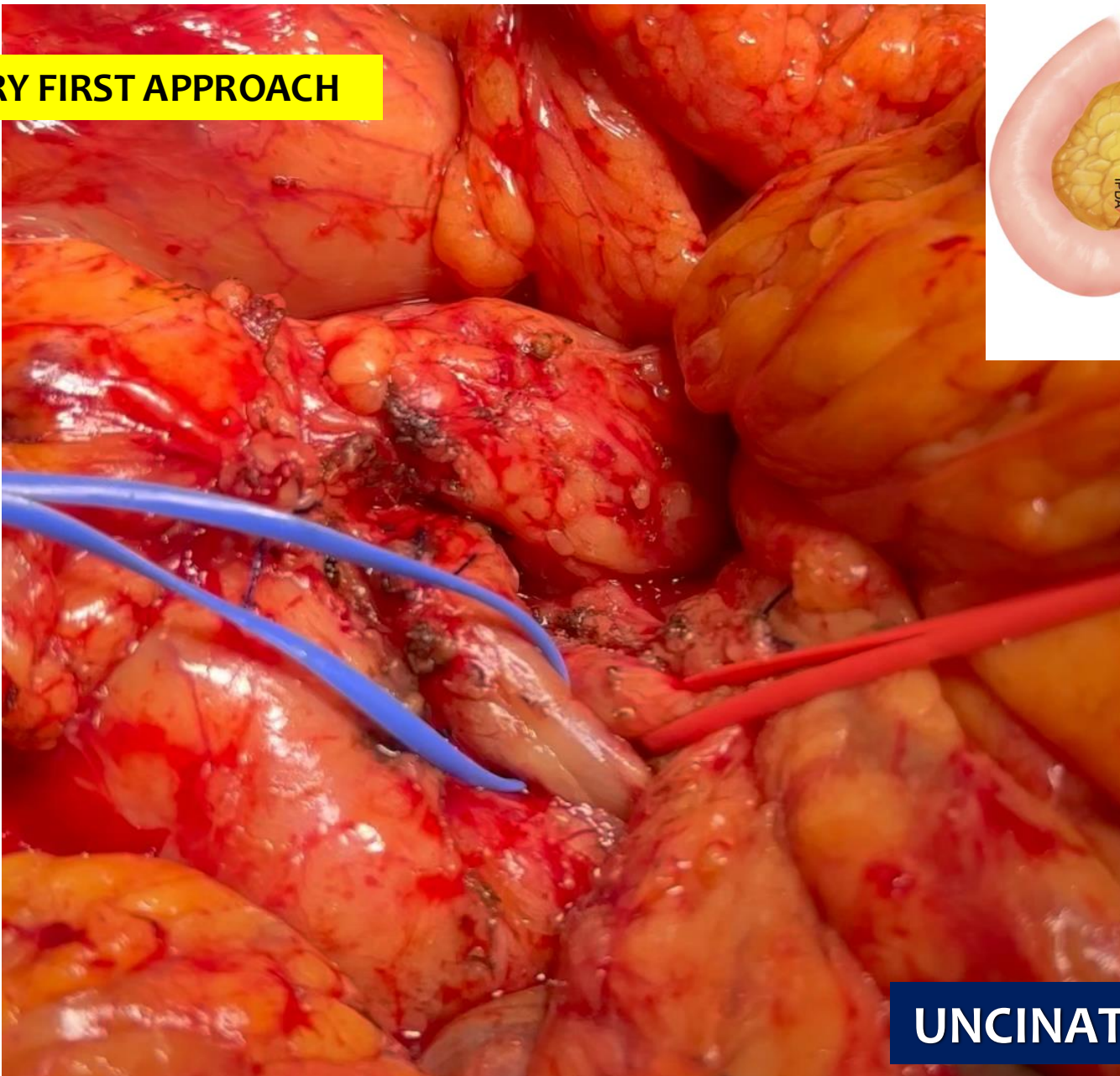
1. Resection without breaching the tumor extension plane, thereby minimizing cell spillage
2. Increases curative (R0) resection, decreases local recurrence
3. Complete resection of peripancreatic retroperitoneal tissue around the plexuses
4. Increased lymph nodal clearance
5. Early assessment of non-resectability (SMA involvement), avoiding useless R2 resections
6. Better delineation of SMA and identification of RHA anomalies
7. Easier en bloc resection and reconstruction of SMV-PV by “no touch” technique
8. Reduced need for graft substitutions
9. Reduced operative time and blood loss (early ligation of IPDA/JA1)



Fernandes ESM, et al. J Gastrointest Oncol 2023

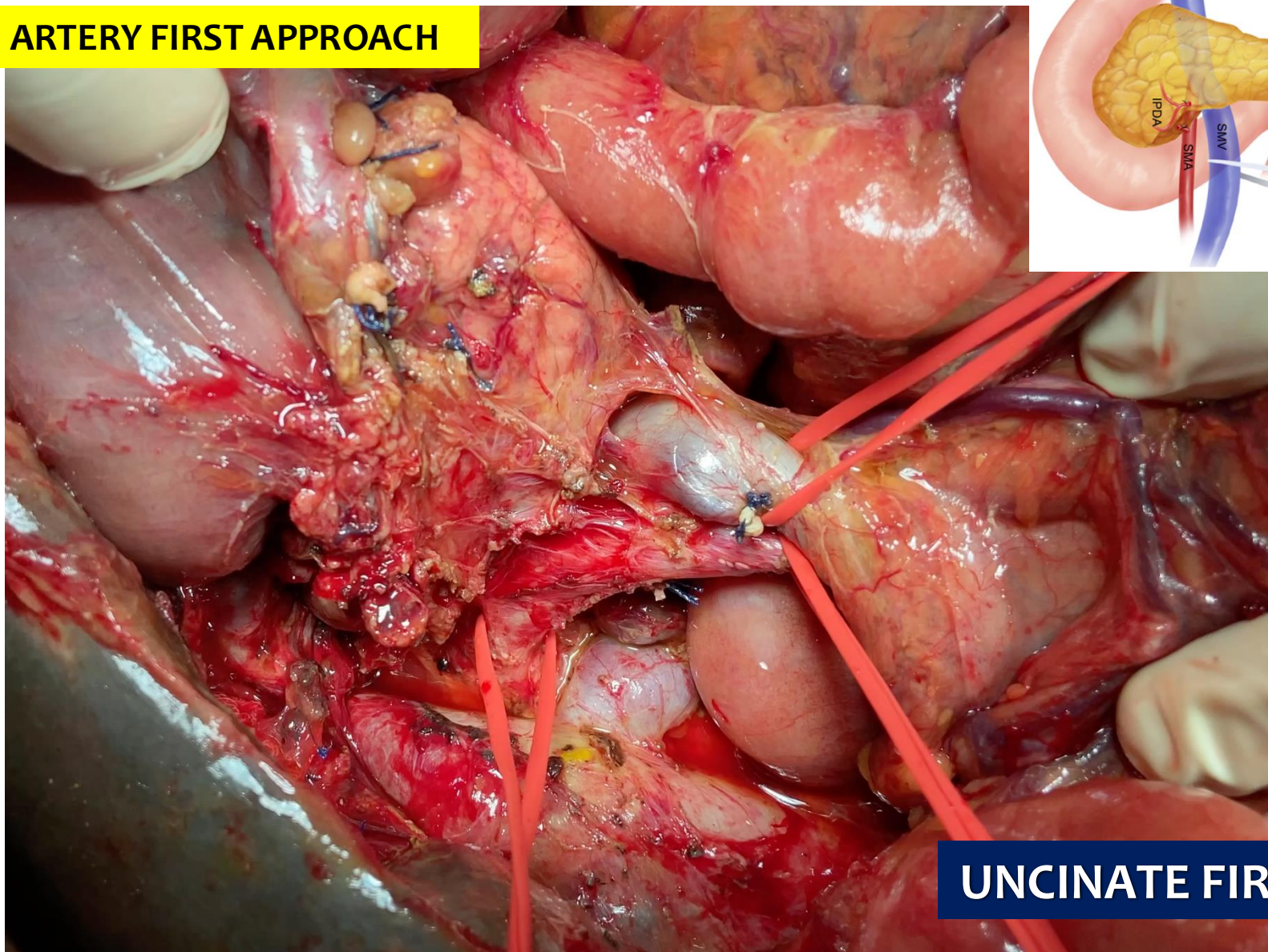
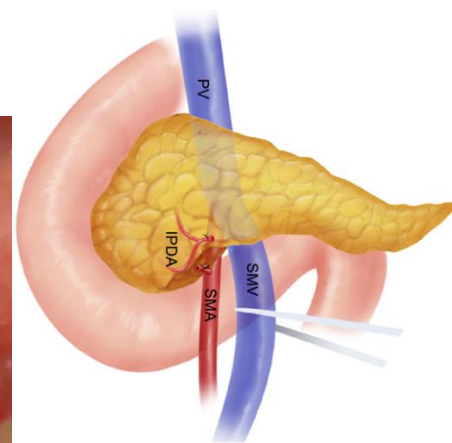
**ARTERY FIRST**

## ARTERY FIRST APPROACH



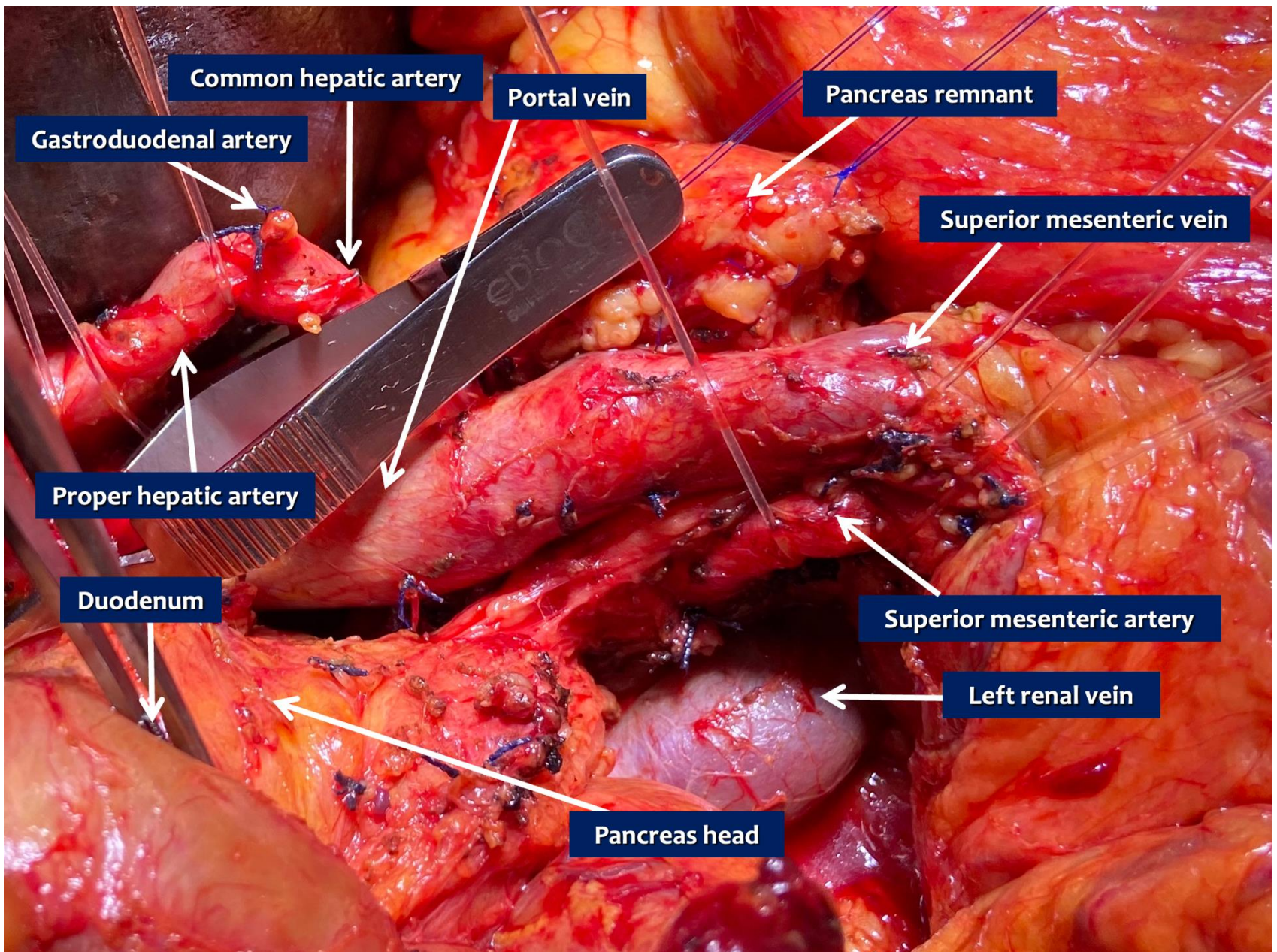
**UNCINATE FIRST**

# ARTERY FIRST APPROACH

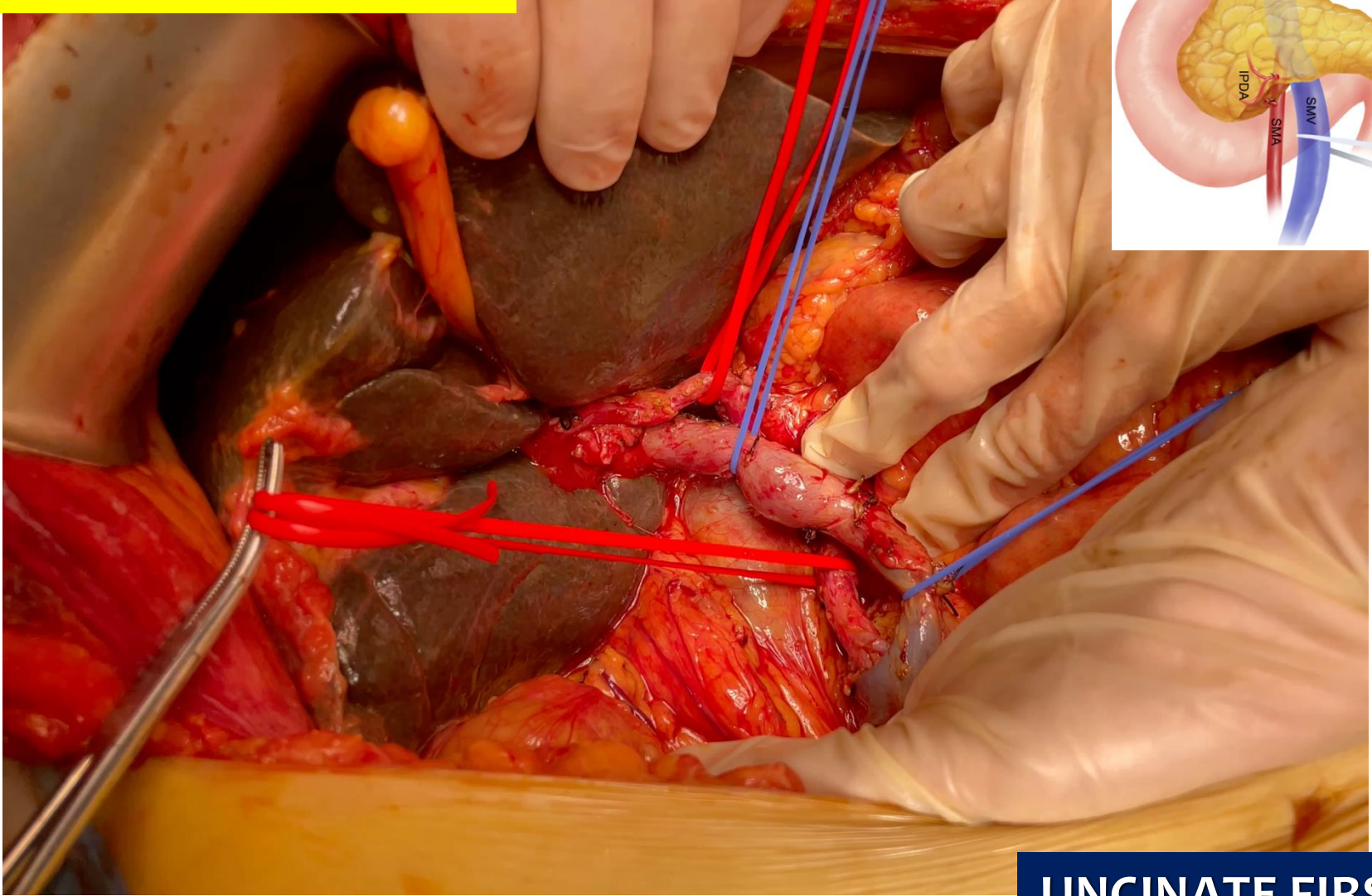


# UNCINATE FIRST



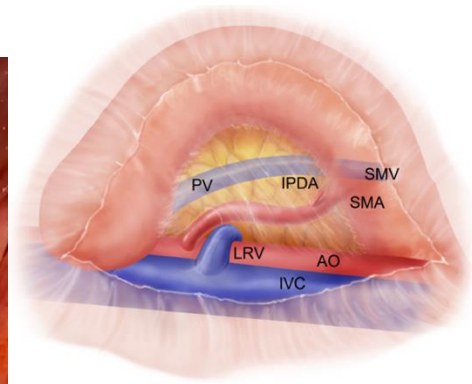
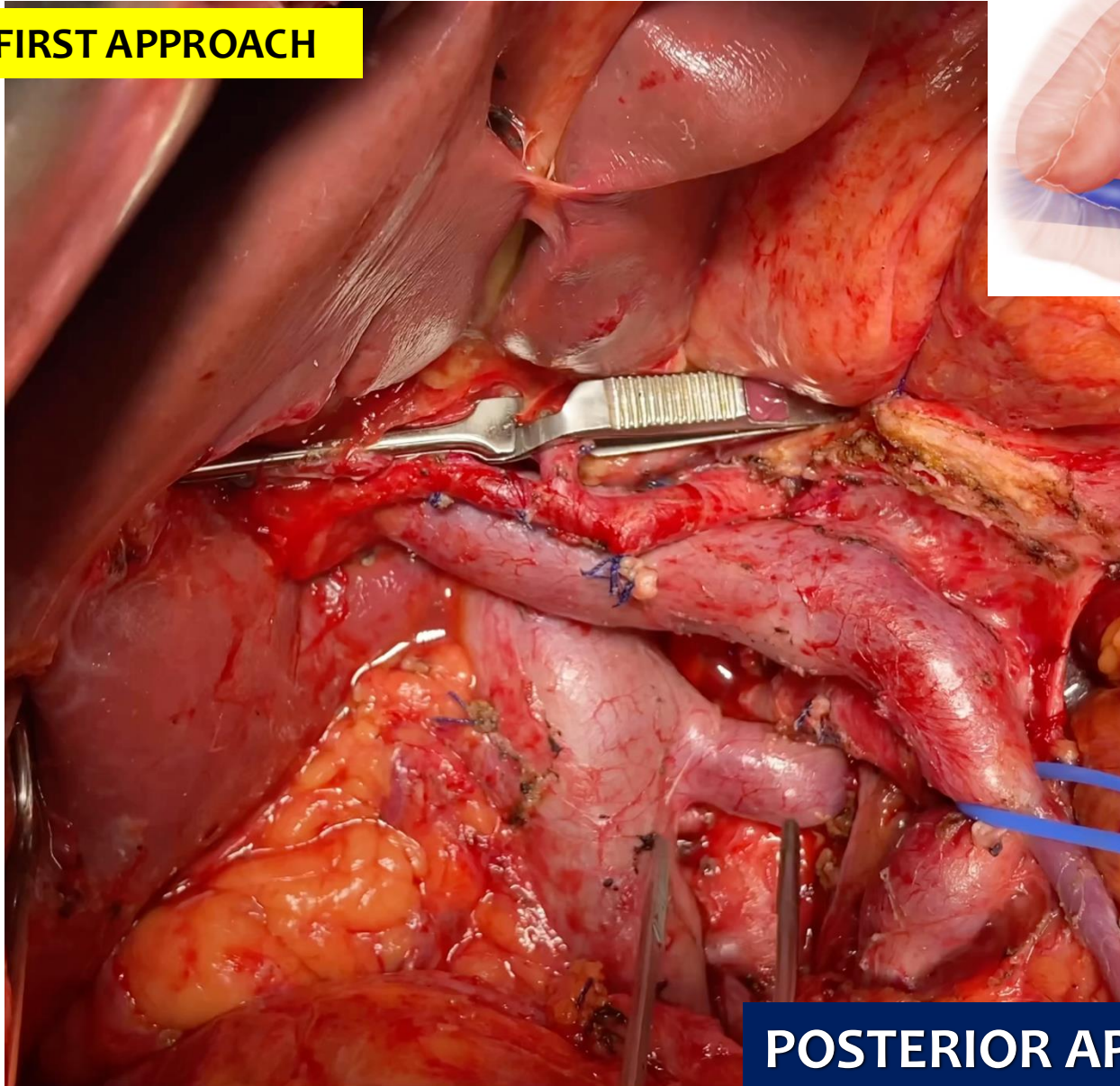


## ARTERY FIRST APPROACH



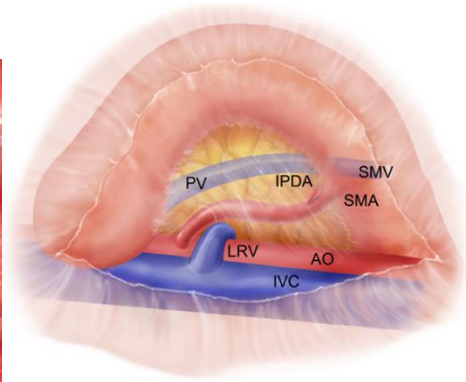
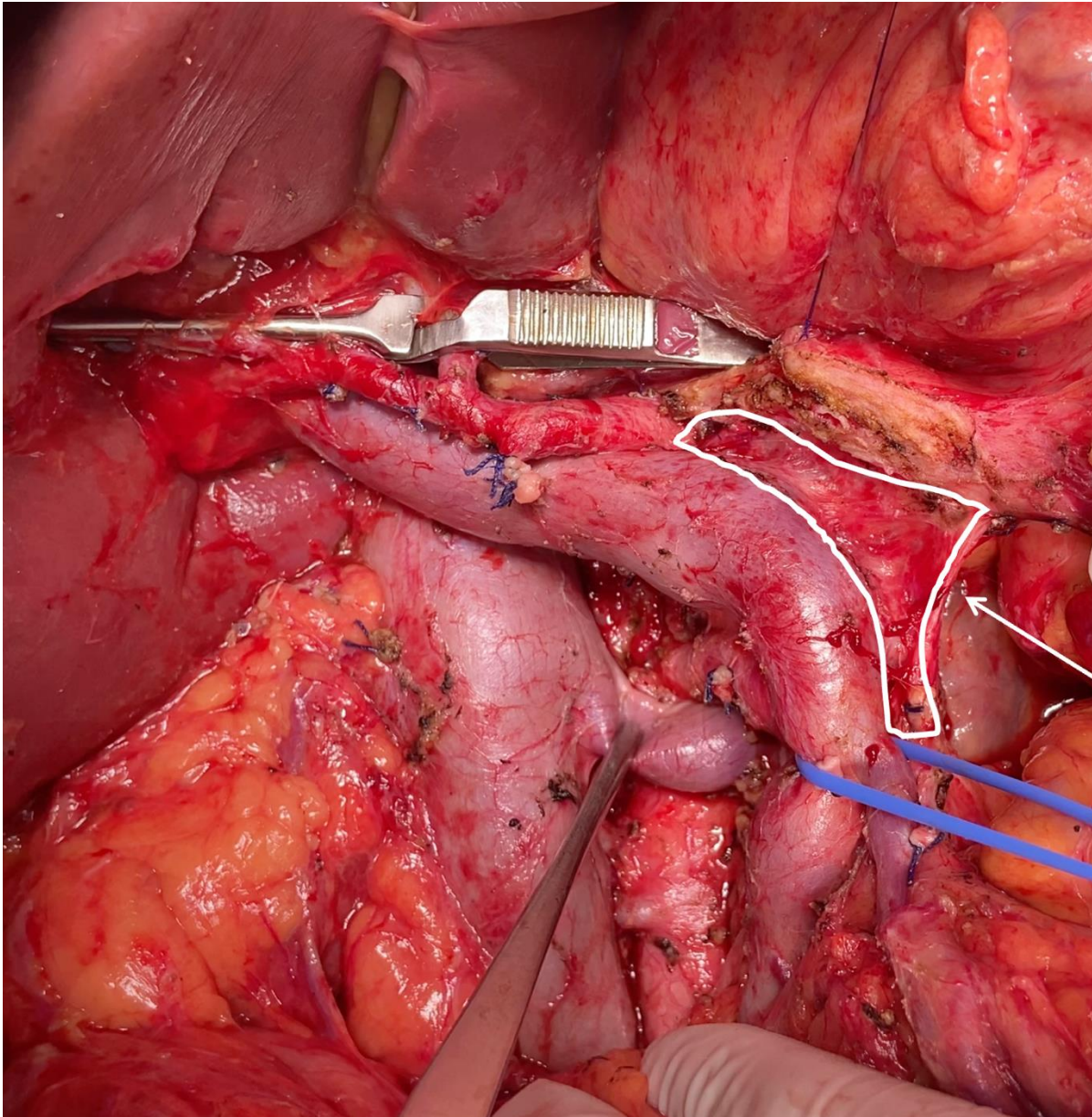
**UNCINATE FIRST**

## ARTERY FIRST APPROACH

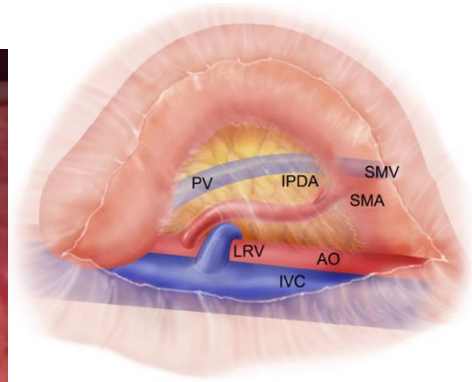
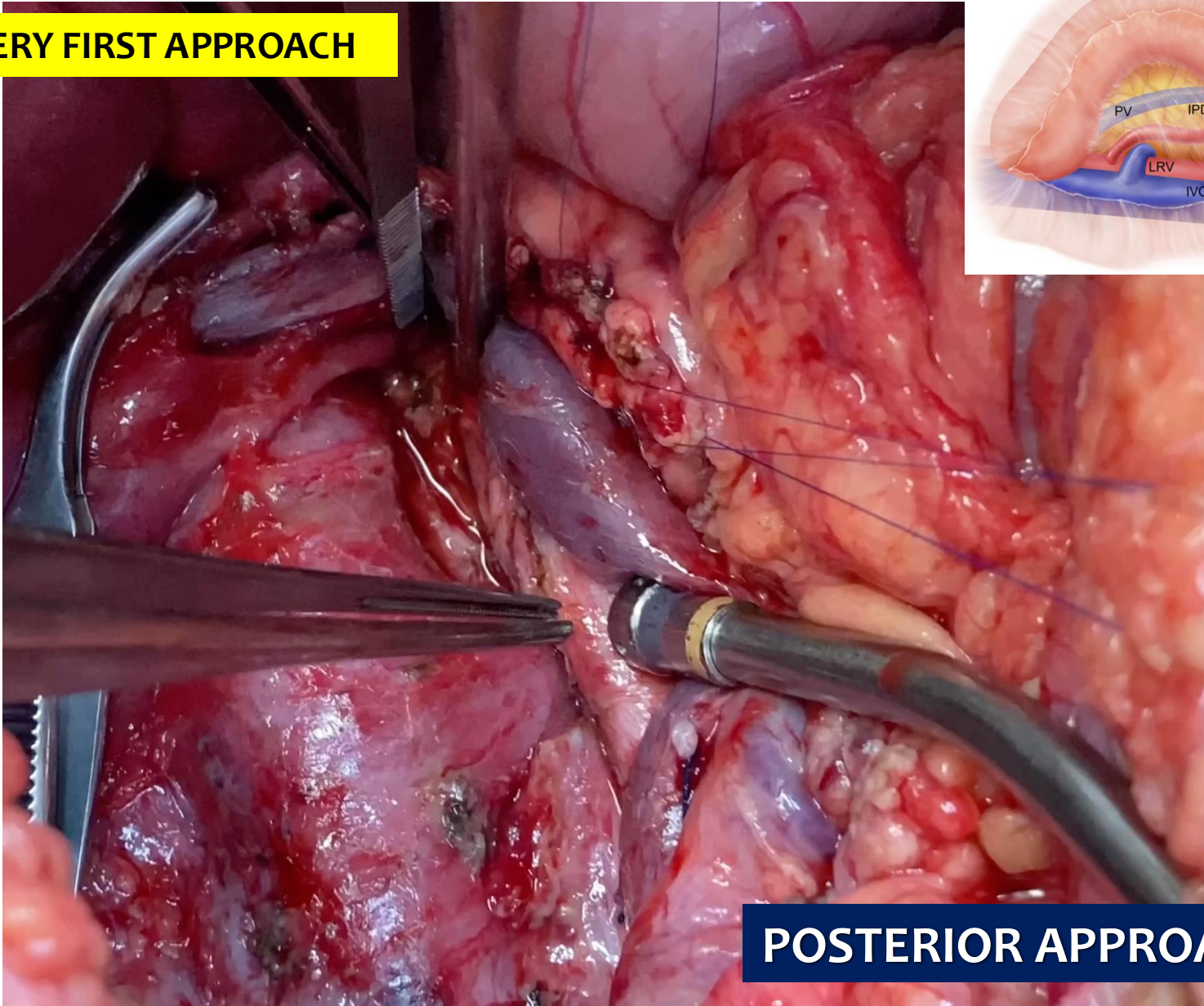


## POSTERIOR APPROACH



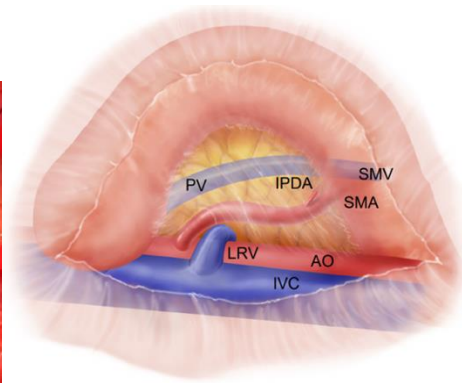
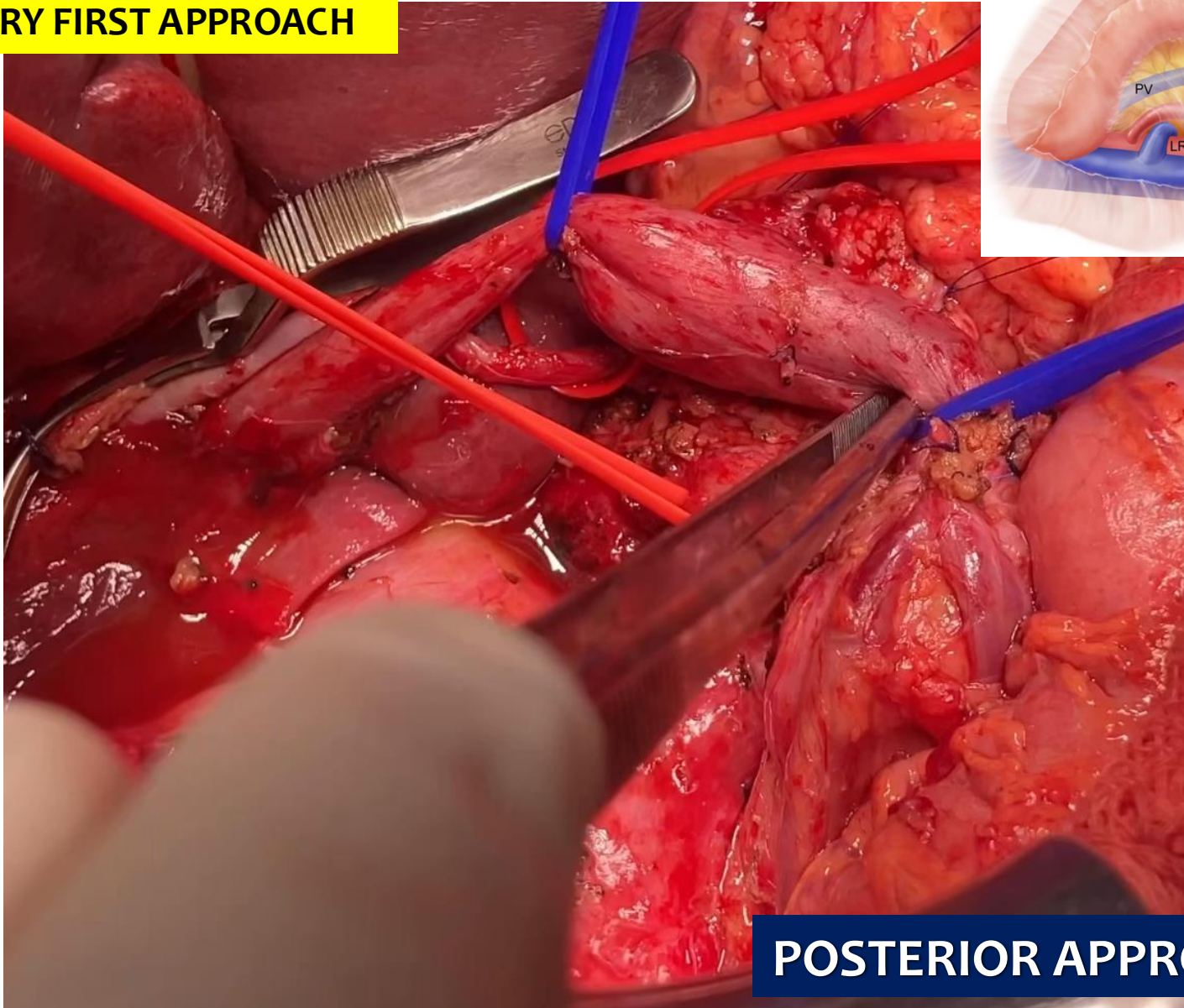


## ARTERY FIRST APPROACH



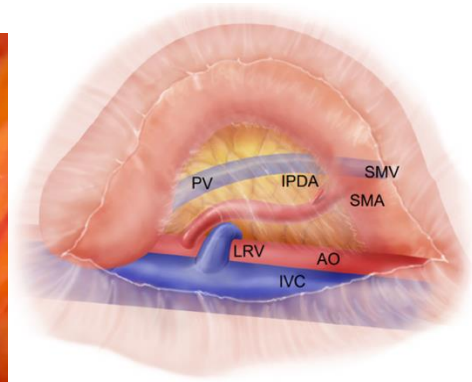
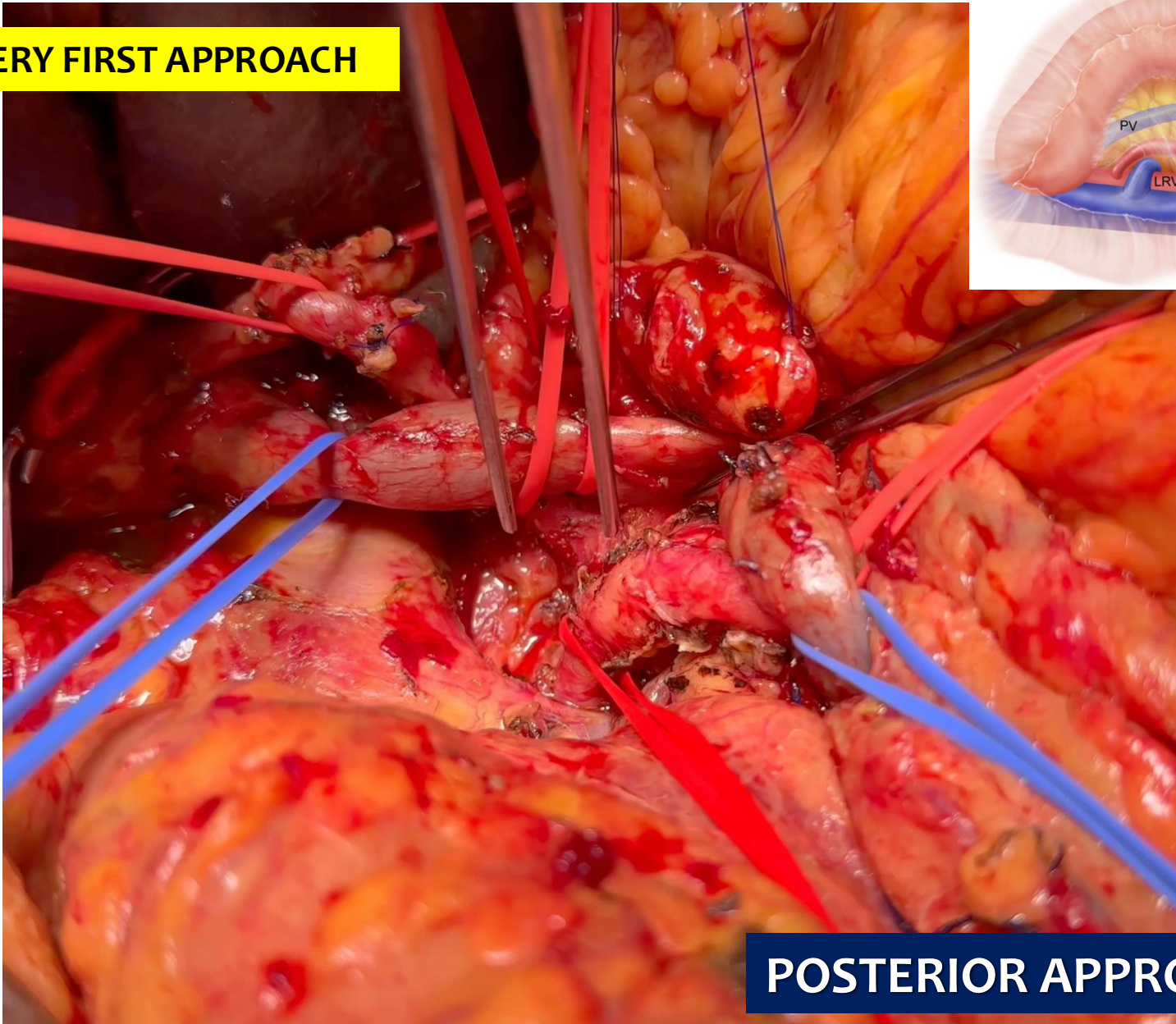
## POSTERIOR APPROACH

## ARTERY FIRST APPROACH



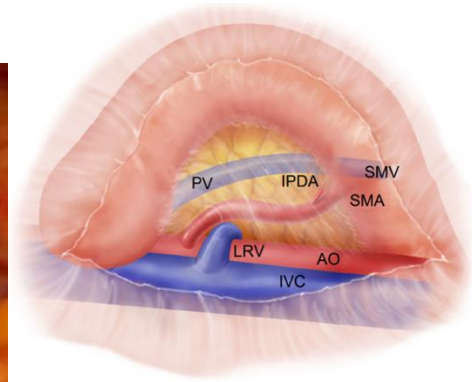
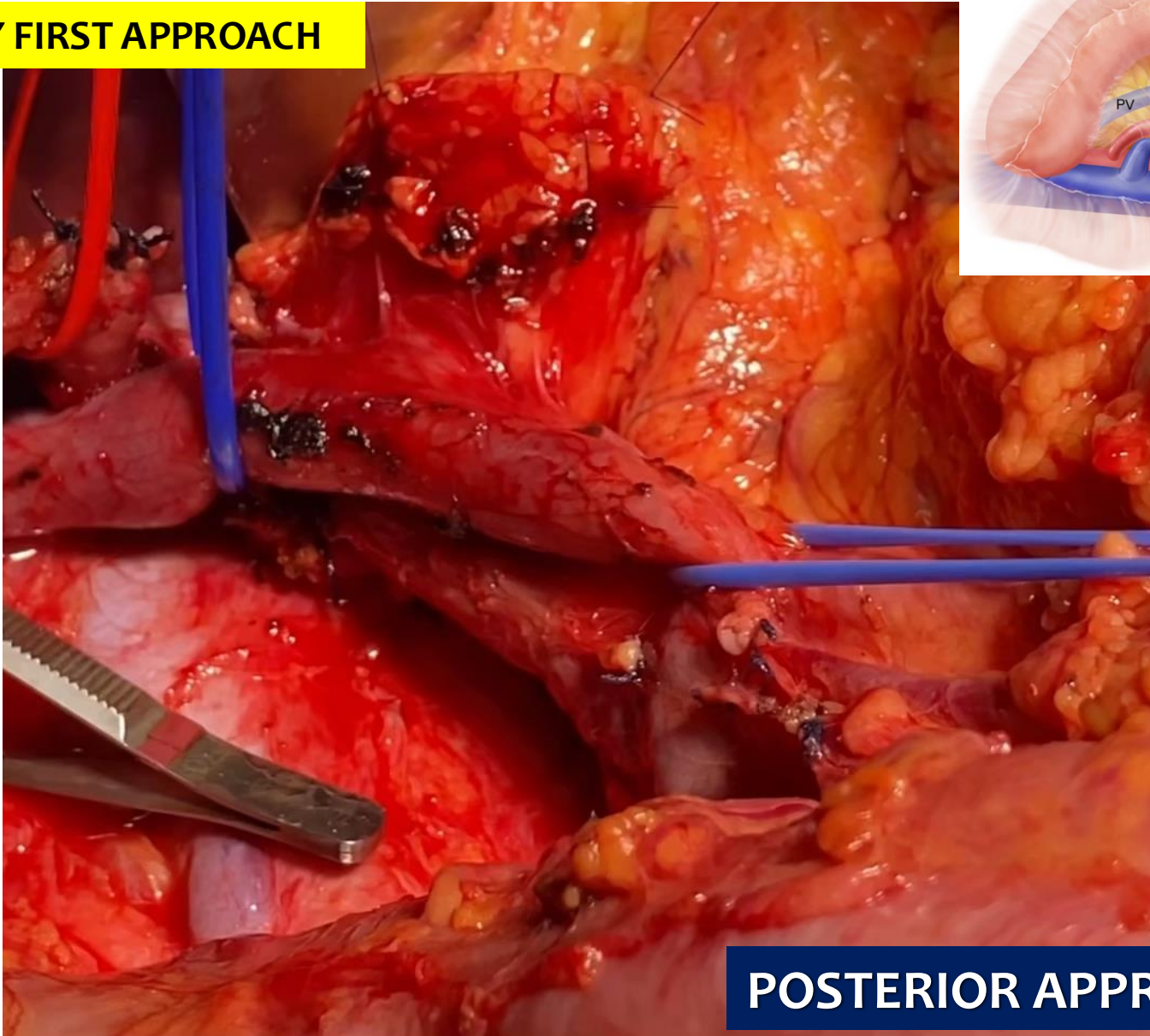
## POSTERIOR APPROACH

## ARTERY FIRST APPROACH



## POSTERIOR APPROACH

# ARTERY FIRST APPROACH



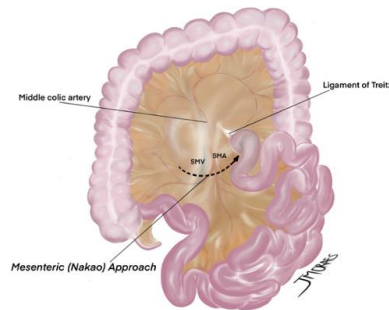
# POSTERIOR APPROACH

# A more radical perspective on surgical approach and outcomes in pancreatic cancer—a narrative review

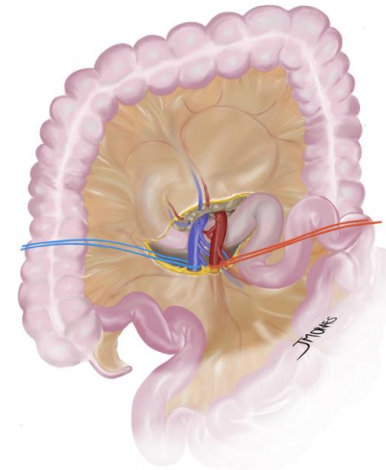
Eduardo de Souza M. Fernandes<sup>1,2,3</sup>, Felipe Pedreira T. de Mello<sup>1,2</sup>, Eduardo Pinho Braga<sup>1</sup>, Gabrielle Oliveira de Souza<sup>1</sup>, Ronaldo Andrade<sup>1,2</sup>, Leandro Savatone Pimentel<sup>1,2</sup>, Camila Liberato Girão<sup>1,2</sup>, Munique Siqueira<sup>1,2</sup>, José Maria A. Moraes-Junior<sup>6,7</sup>, Romulo Varella de Oliveira<sup>4</sup>, Nicolas Goldaracena<sup>5</sup>, Orlando Jorge M. Torres<sup>6,7</sup>

## MESENTERIC APPROACH

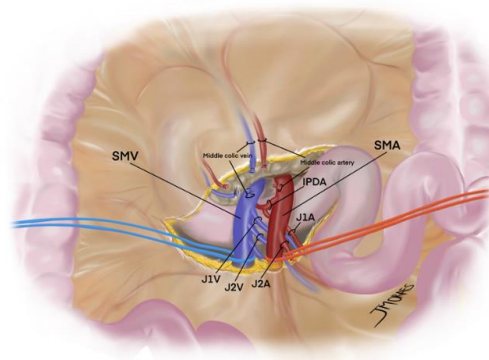
A



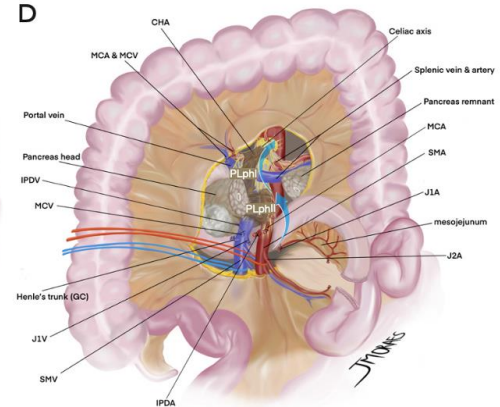
B



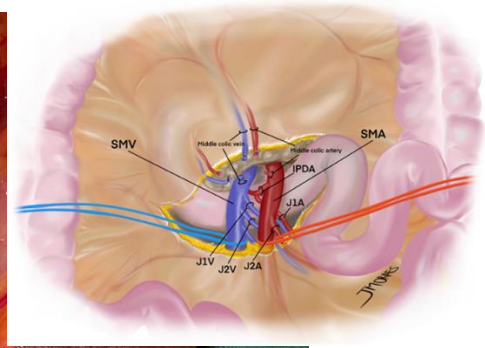
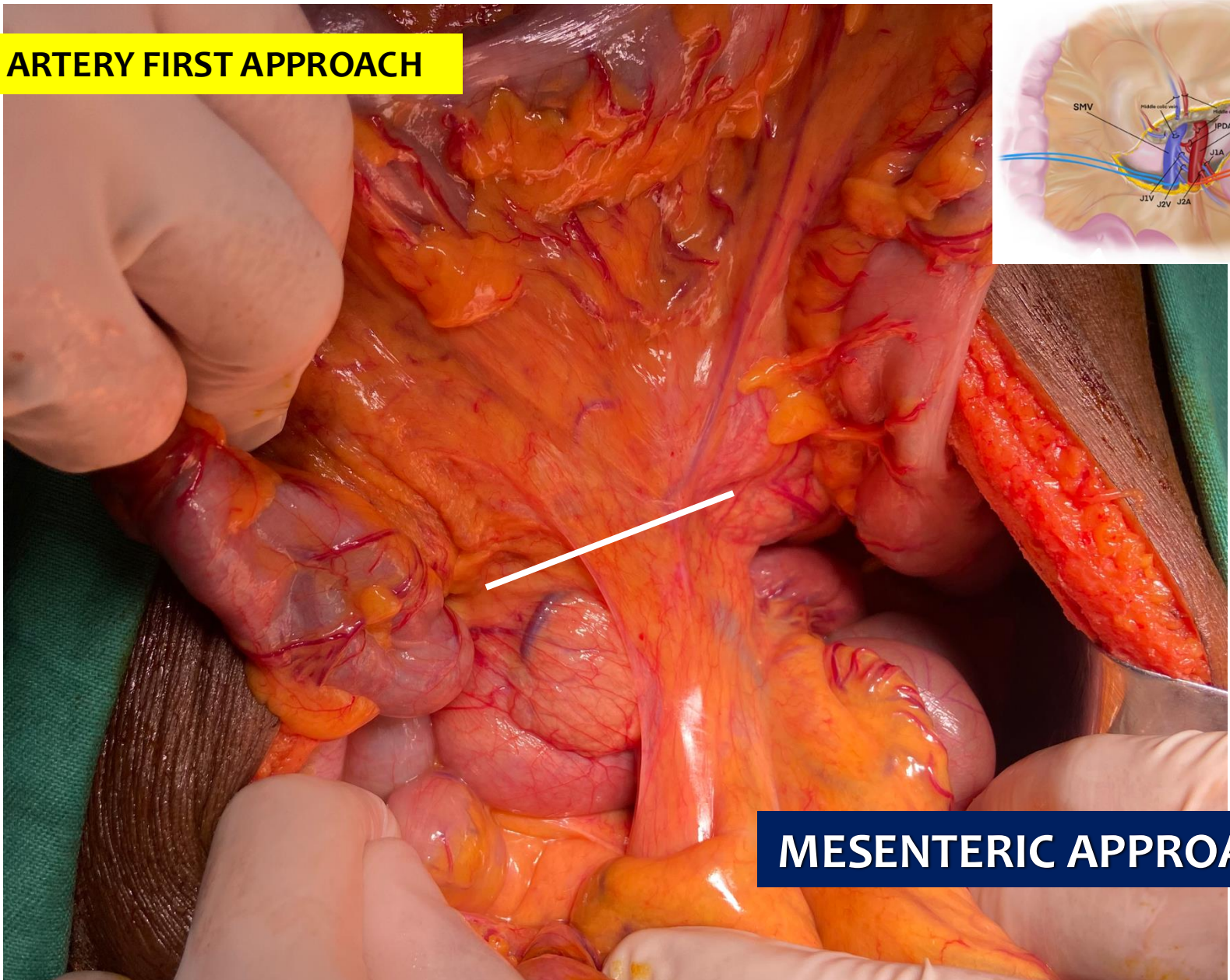
C



D

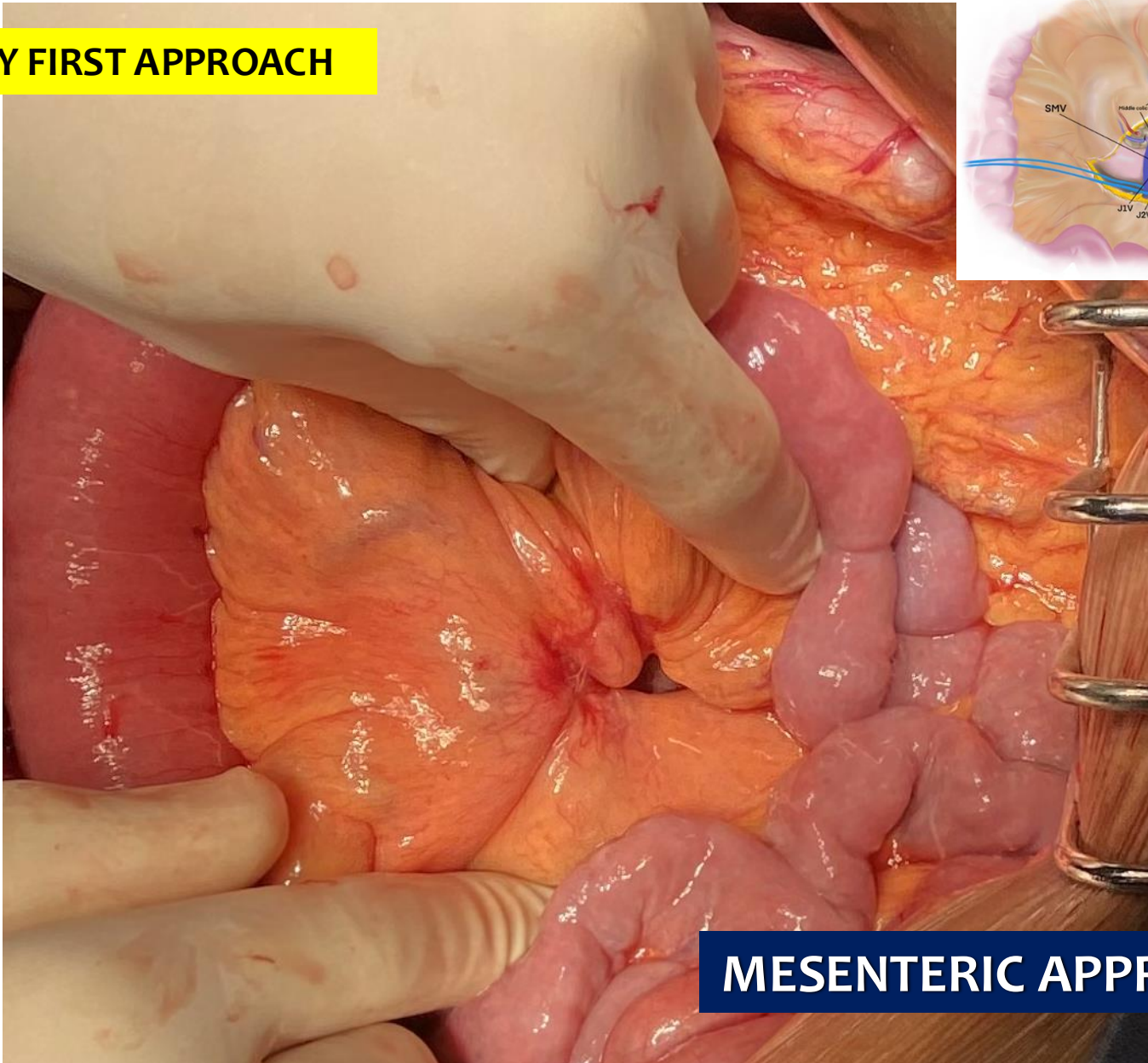


## ARTERY FIRST APPROACH



## MESENTERIC APPROACH

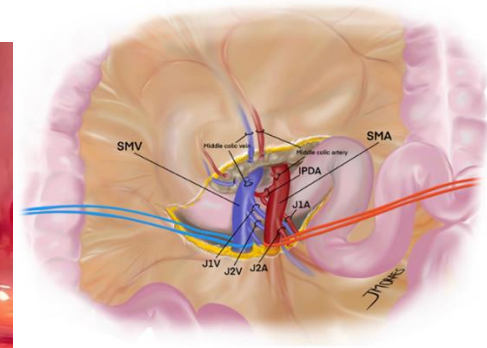
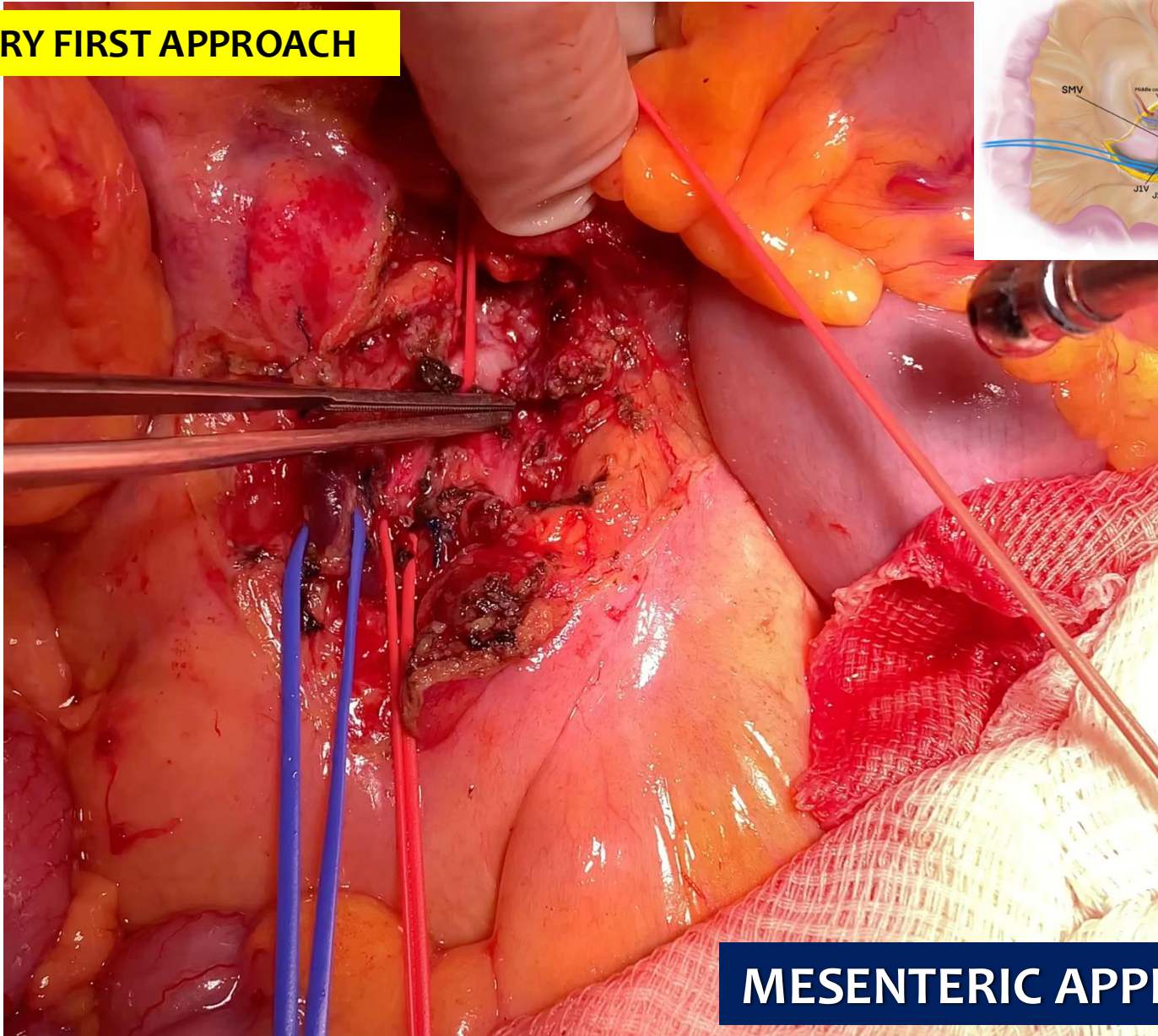
## ARTERY FIRST APPROACH



## MESENTERIC APPROACH



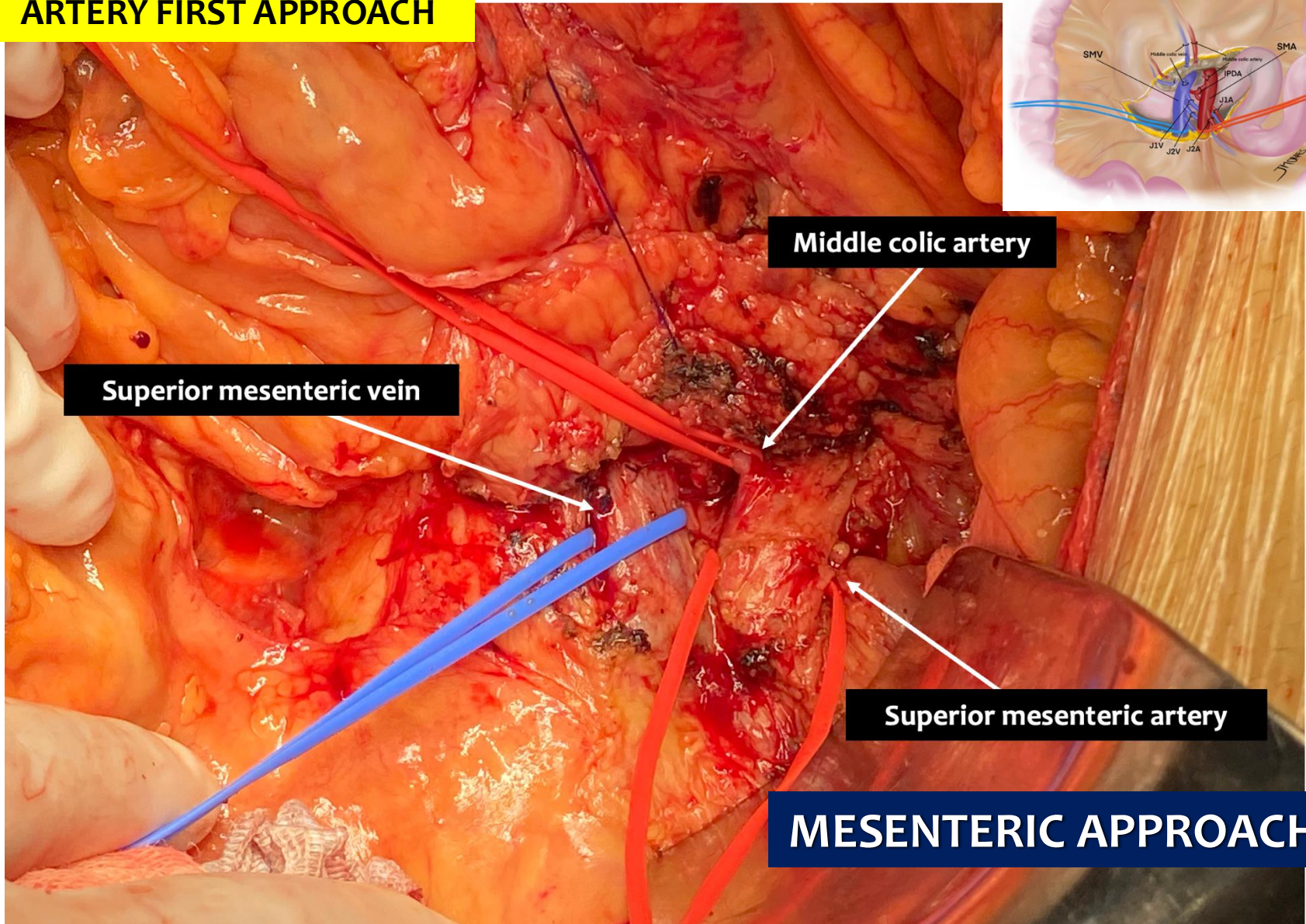
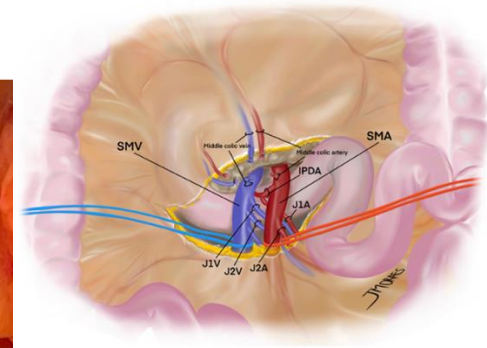
# ARTERY FIRST APPROACH



# MESENTERIC APPROACH



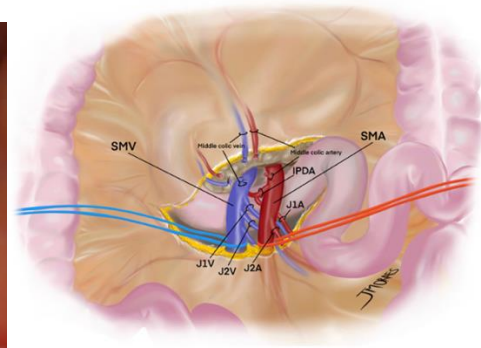
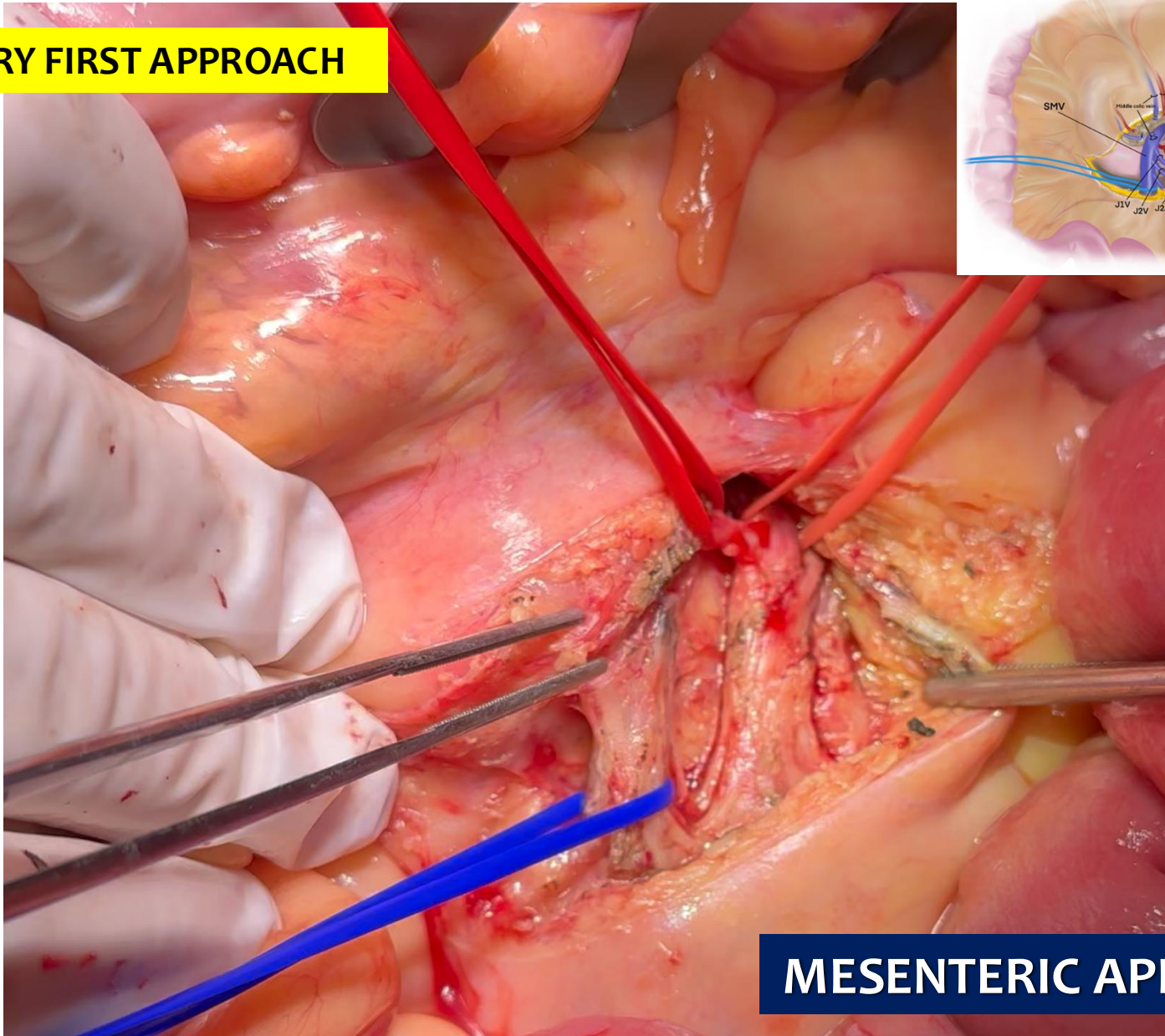
# ARTERY FIRST APPROACH



# MESENTERIC APPROACH

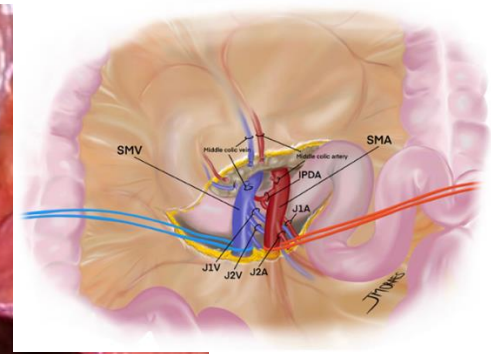
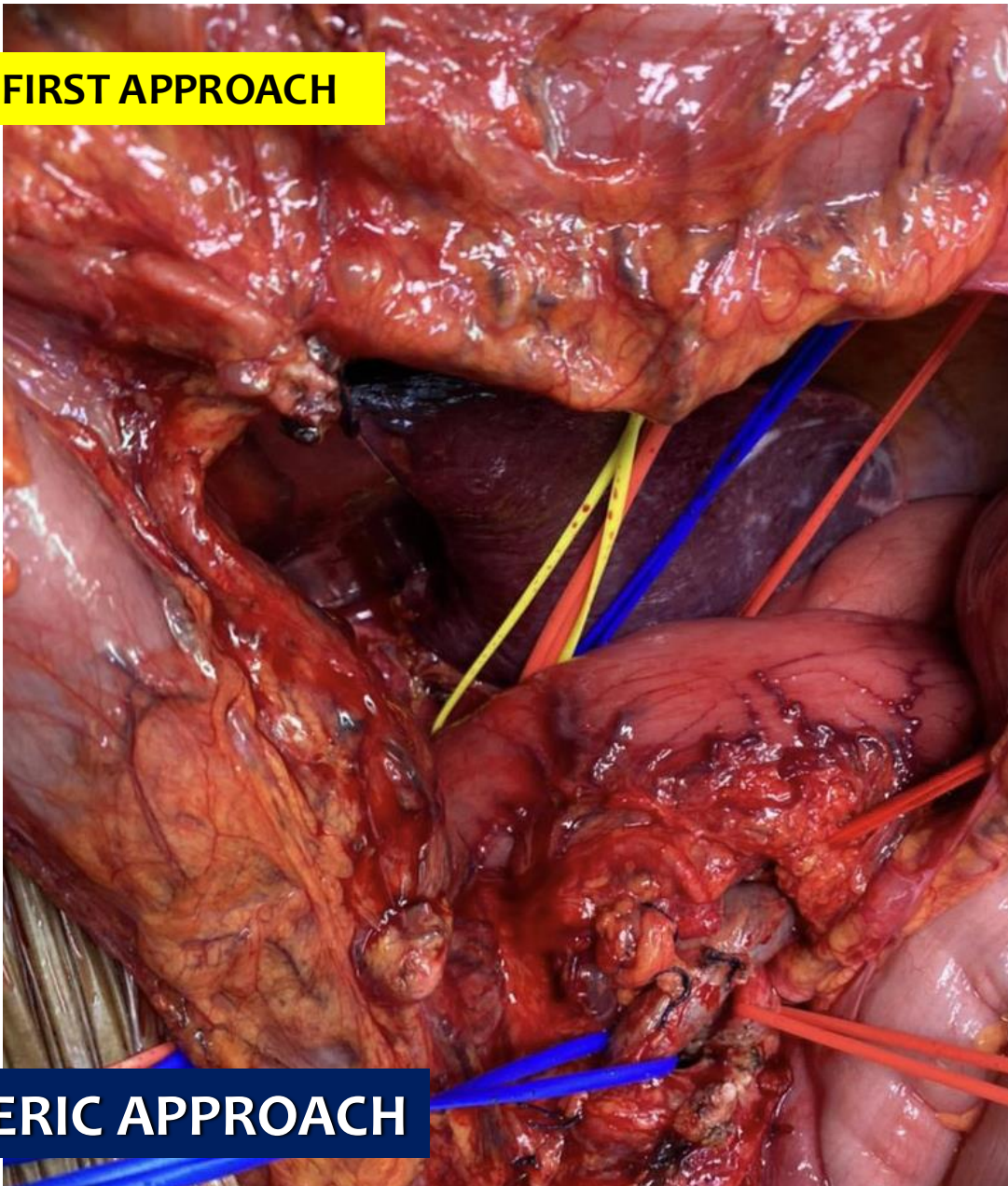


# ARTERY FIRST APPROACH



# MESENTERIC APPROACH

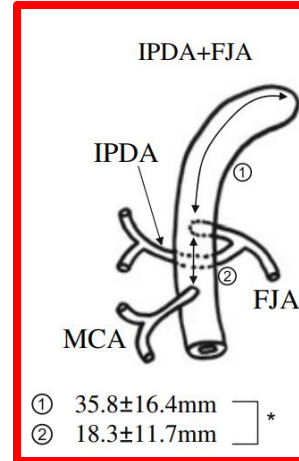
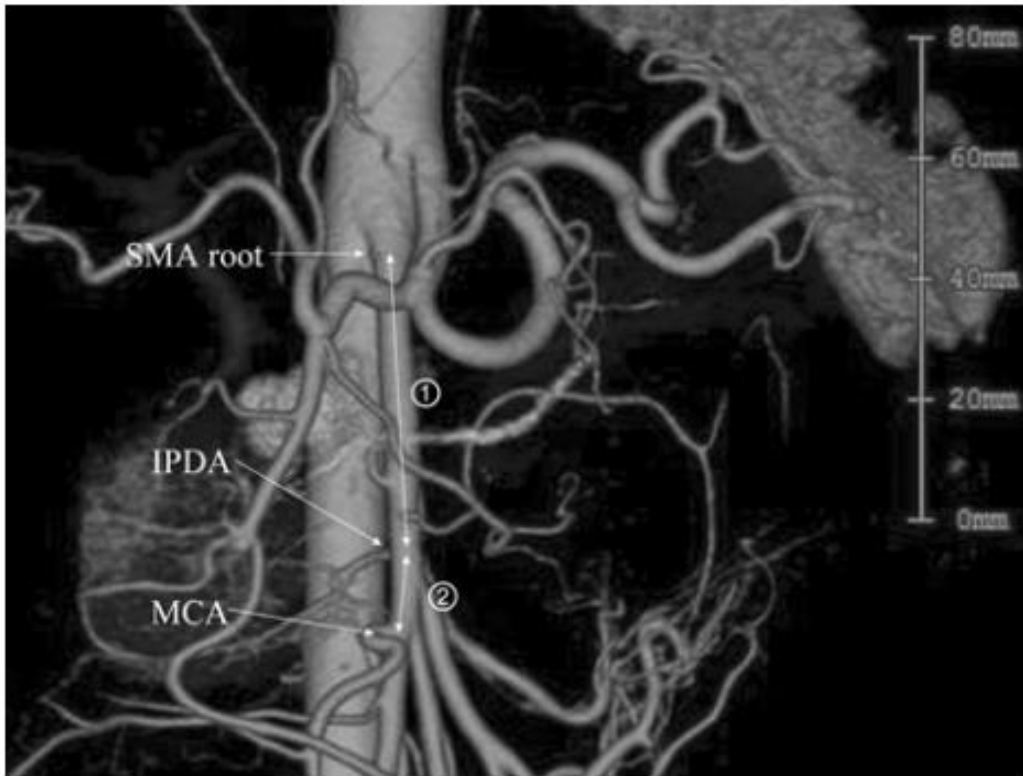
## ARTERY FIRST APPROACH



## MESENTERIC APPROACH

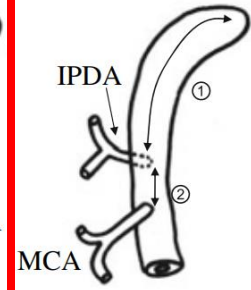


# INFERIOR PANCREATODUODENAL ARTERY



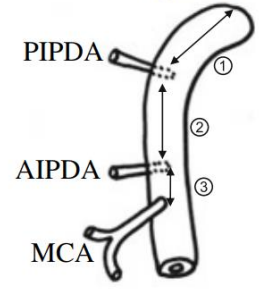
① 35.8±16.4mm  
② 18.3±11.7mm ]\*

IPDA independent



① 36.3±15.2mm  
② 18.6±9.2mm ]\*

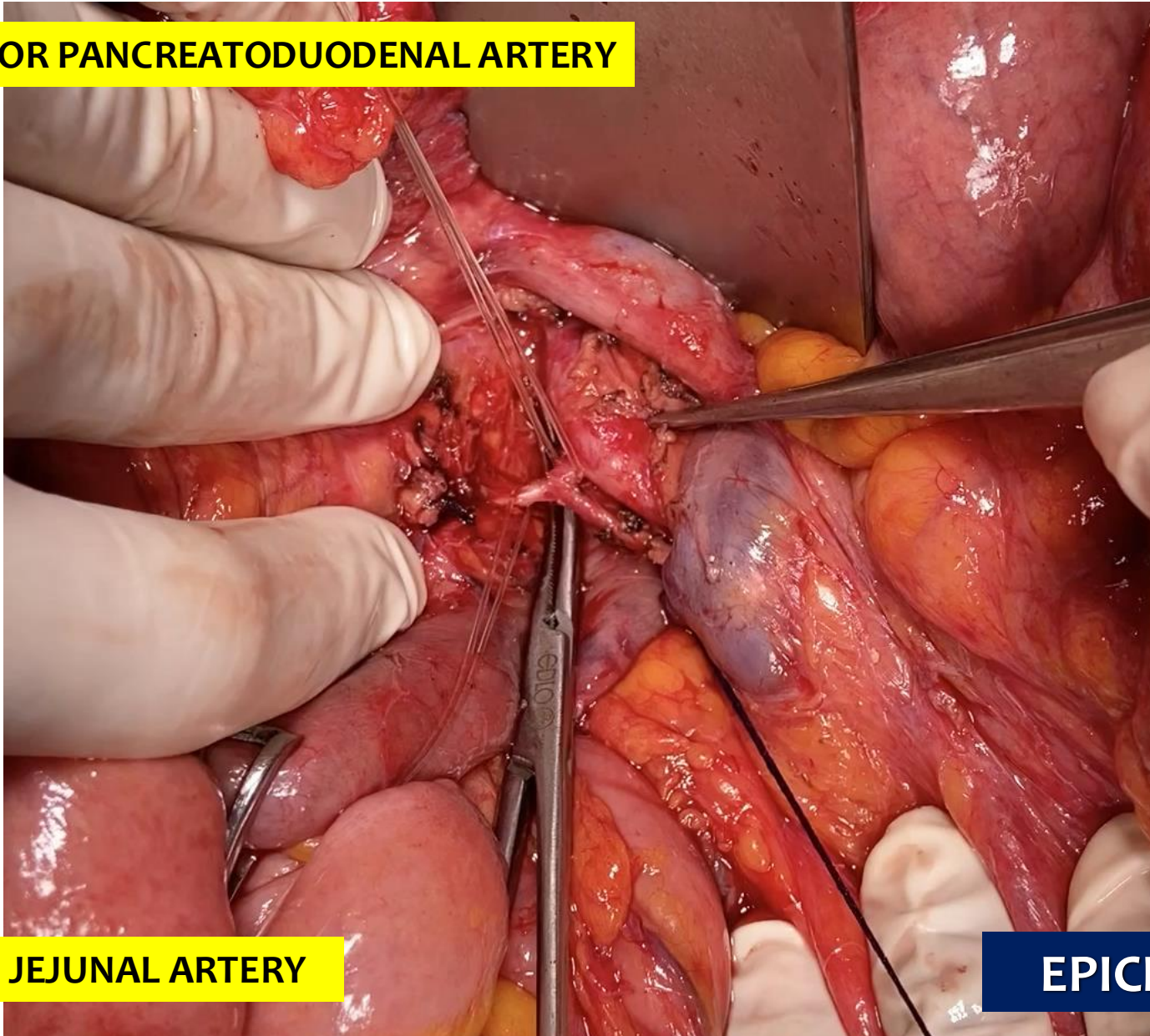
AIPDA/PIPDA independent



① 18.8±7.2mm  
② 19.2±6.2mm  
③ 17.6±4.2mm

## IPDA

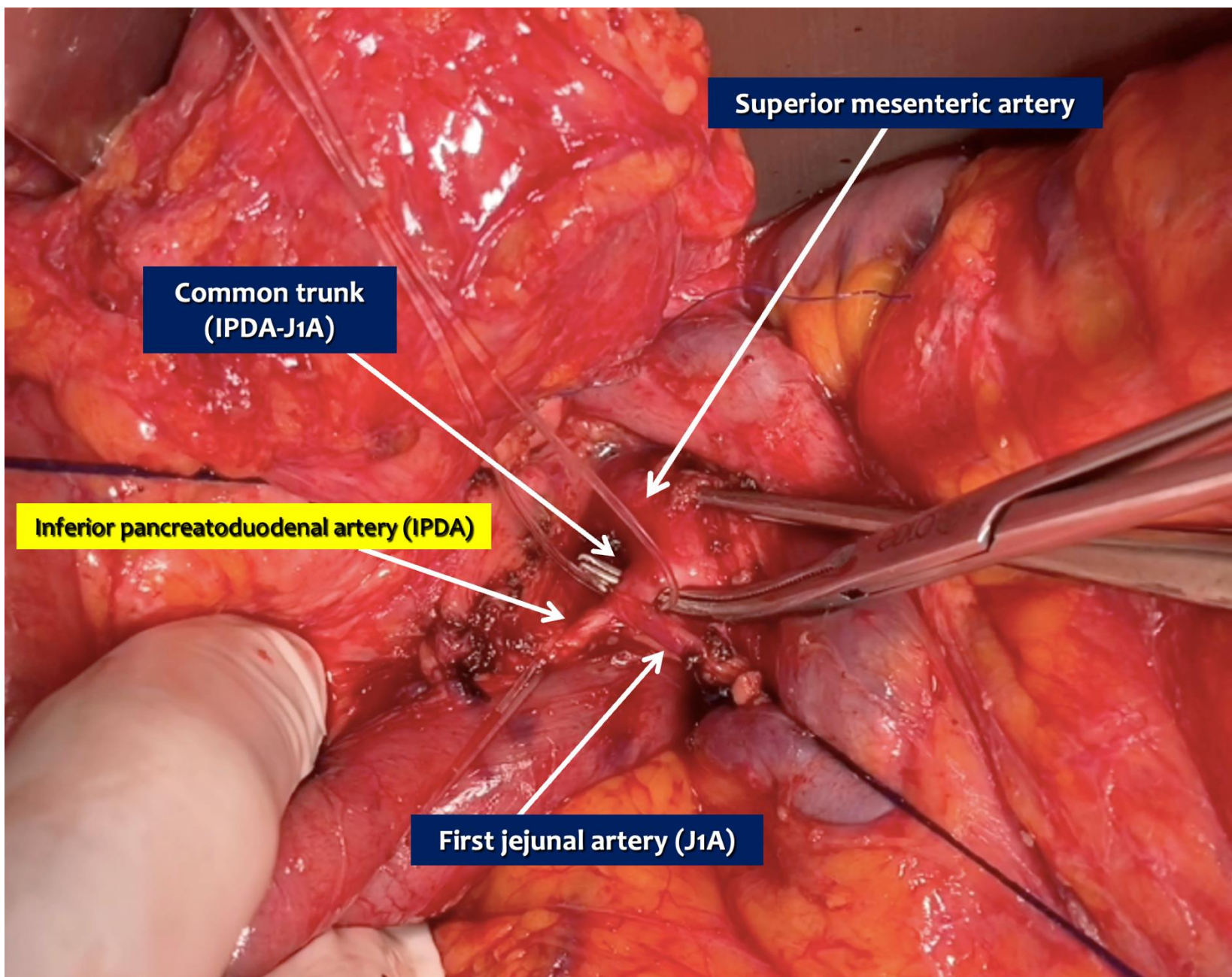
**INFERIOR PANCREATODUODENAL ARTERY**



**FIRST JEJUNAL ARTERY**

**EPICENTER**





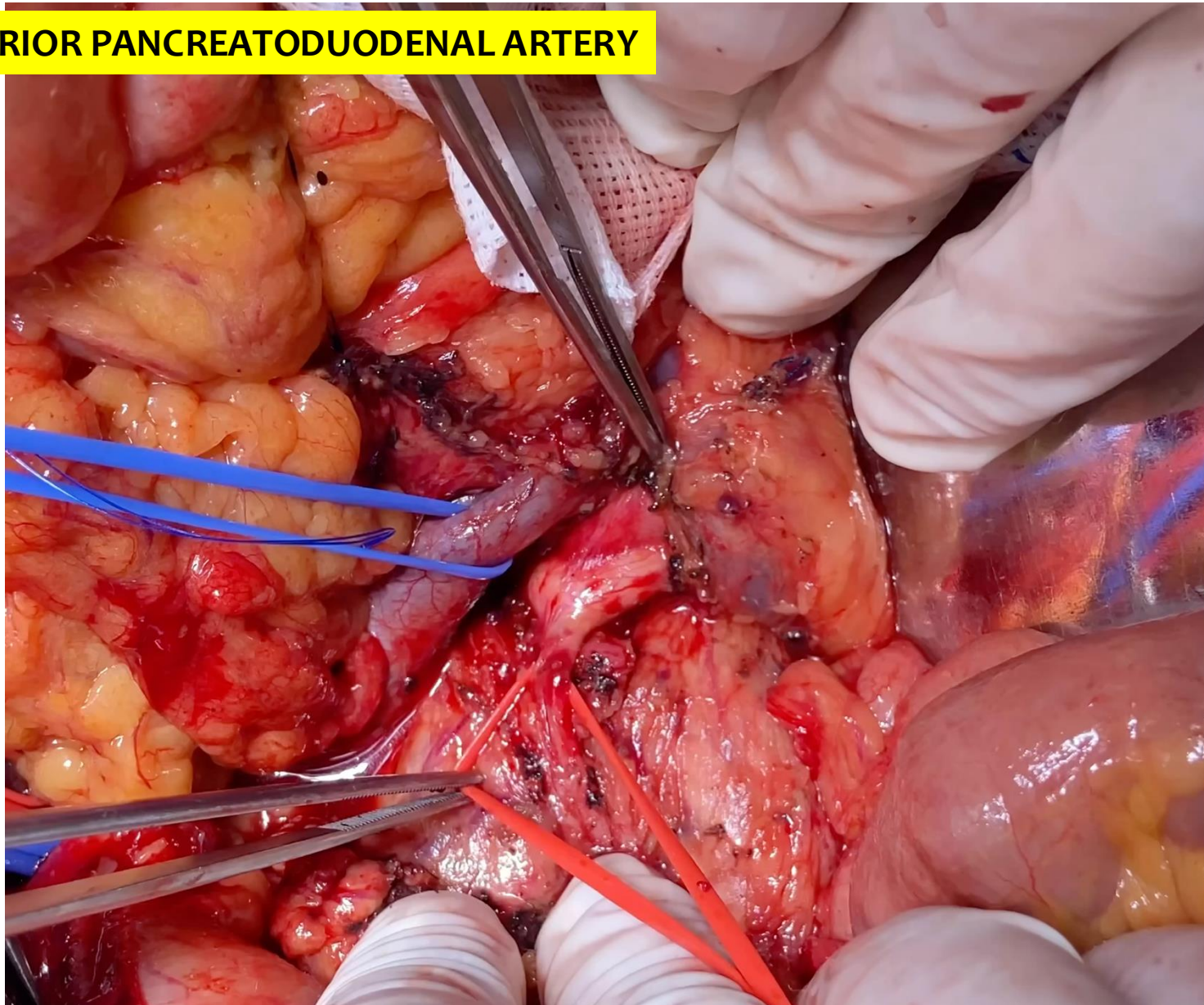
Superior mesenteric artery

Common trunk  
(IPDA-J1A)

Inferior pancreaticoduodenal artery (IPDA)

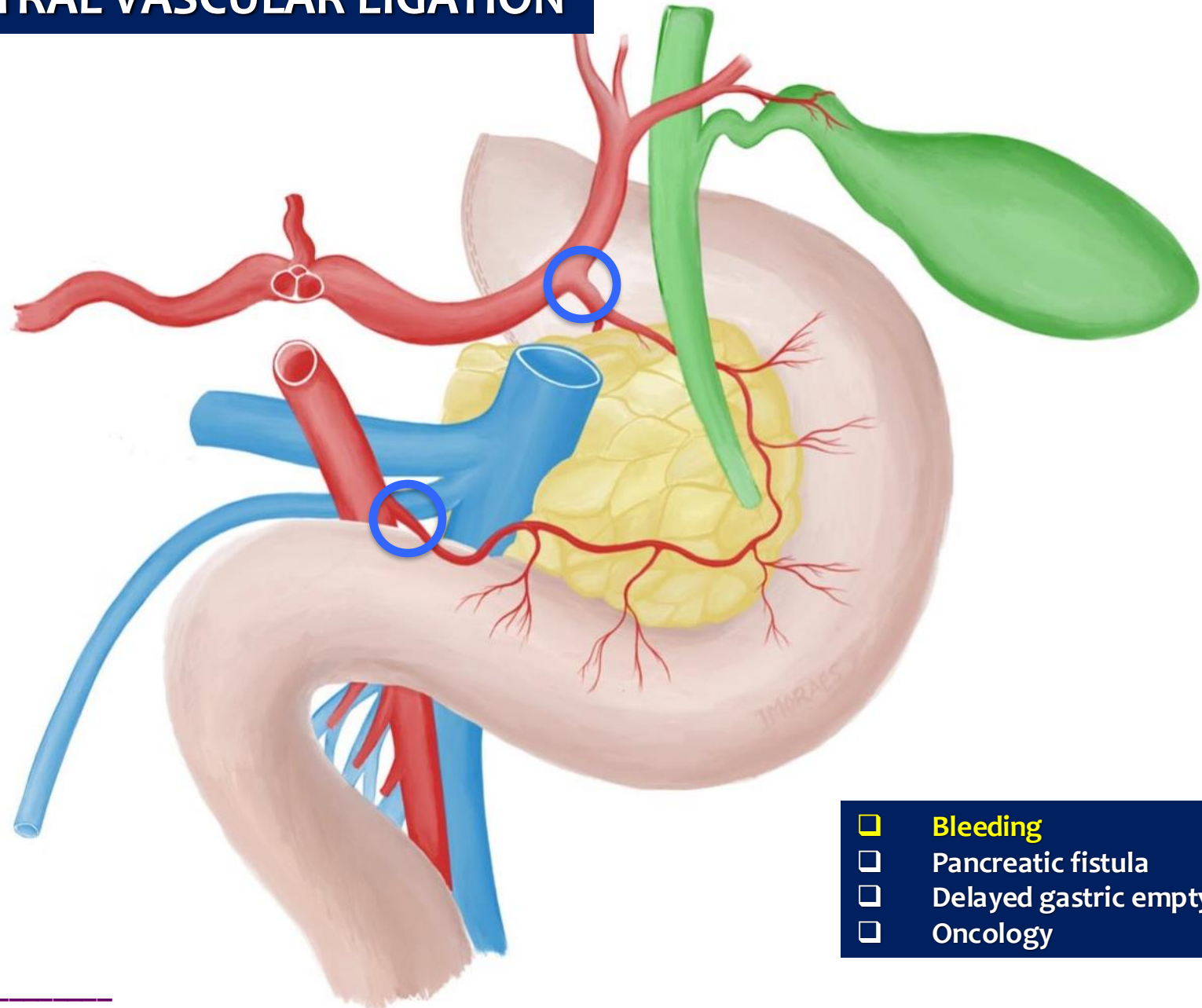
First jejunal artery (J1A)

## INFERIOR PANCREATODUODENAL ARTERY

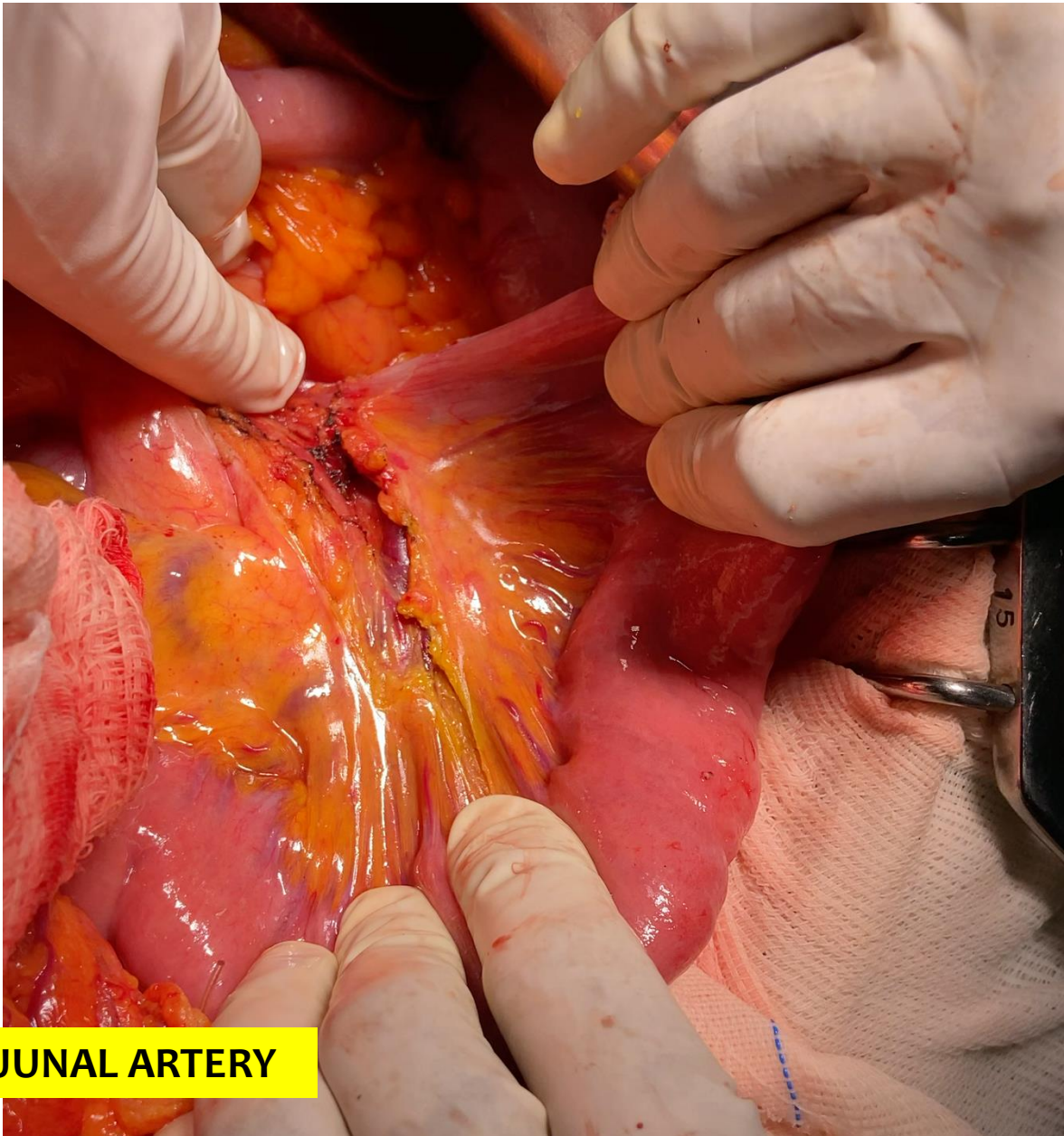




# CENTRAL VASCULAR LIGATION

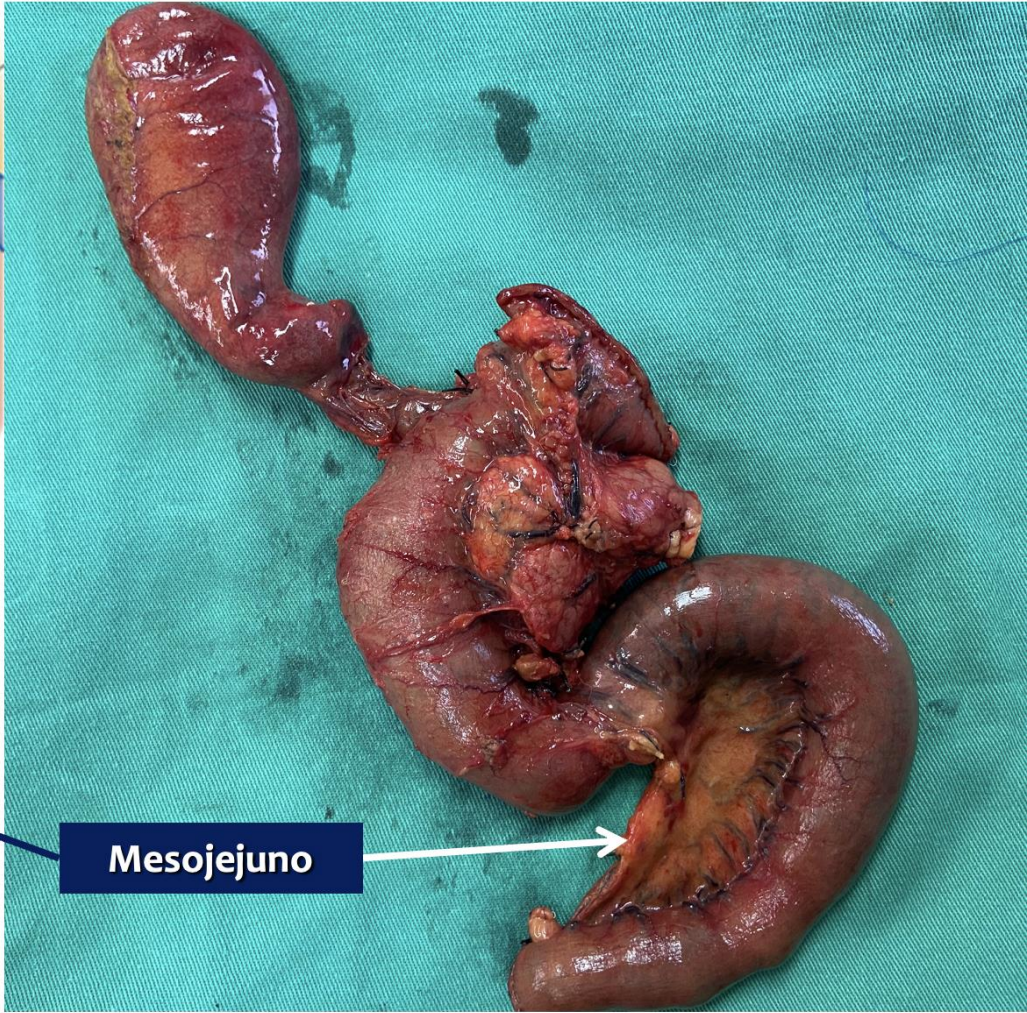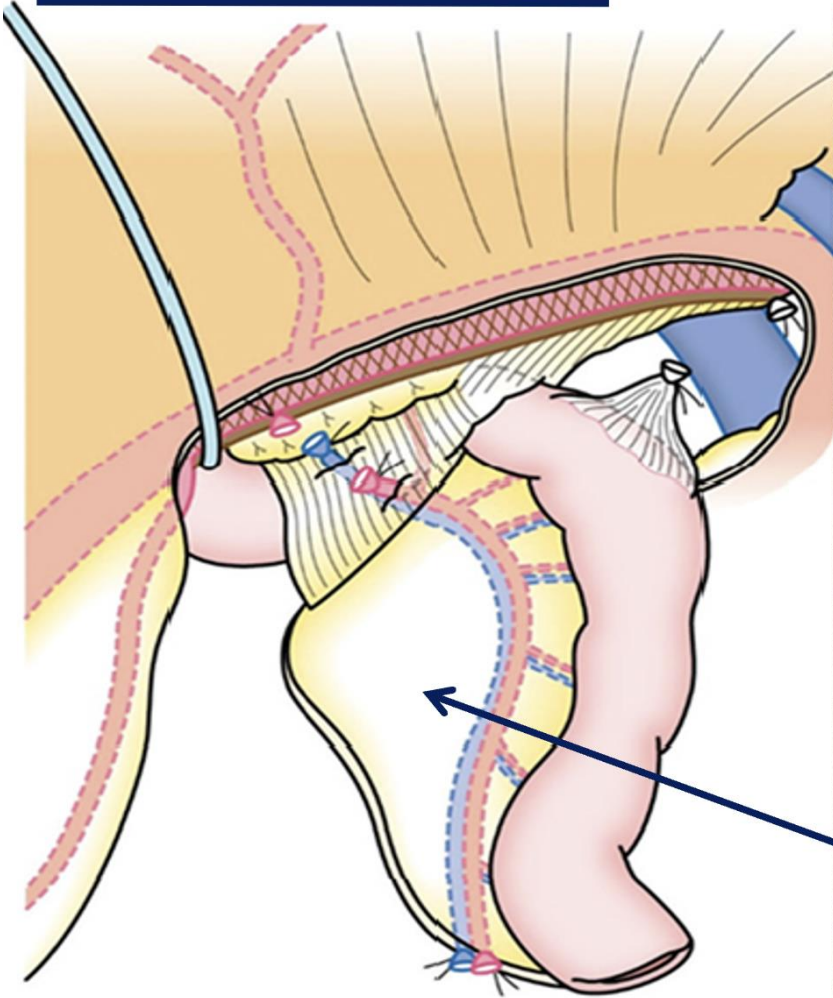


- Bleeding
- Pancreatic fistula
- Delayed gastric emptying
- Oncology

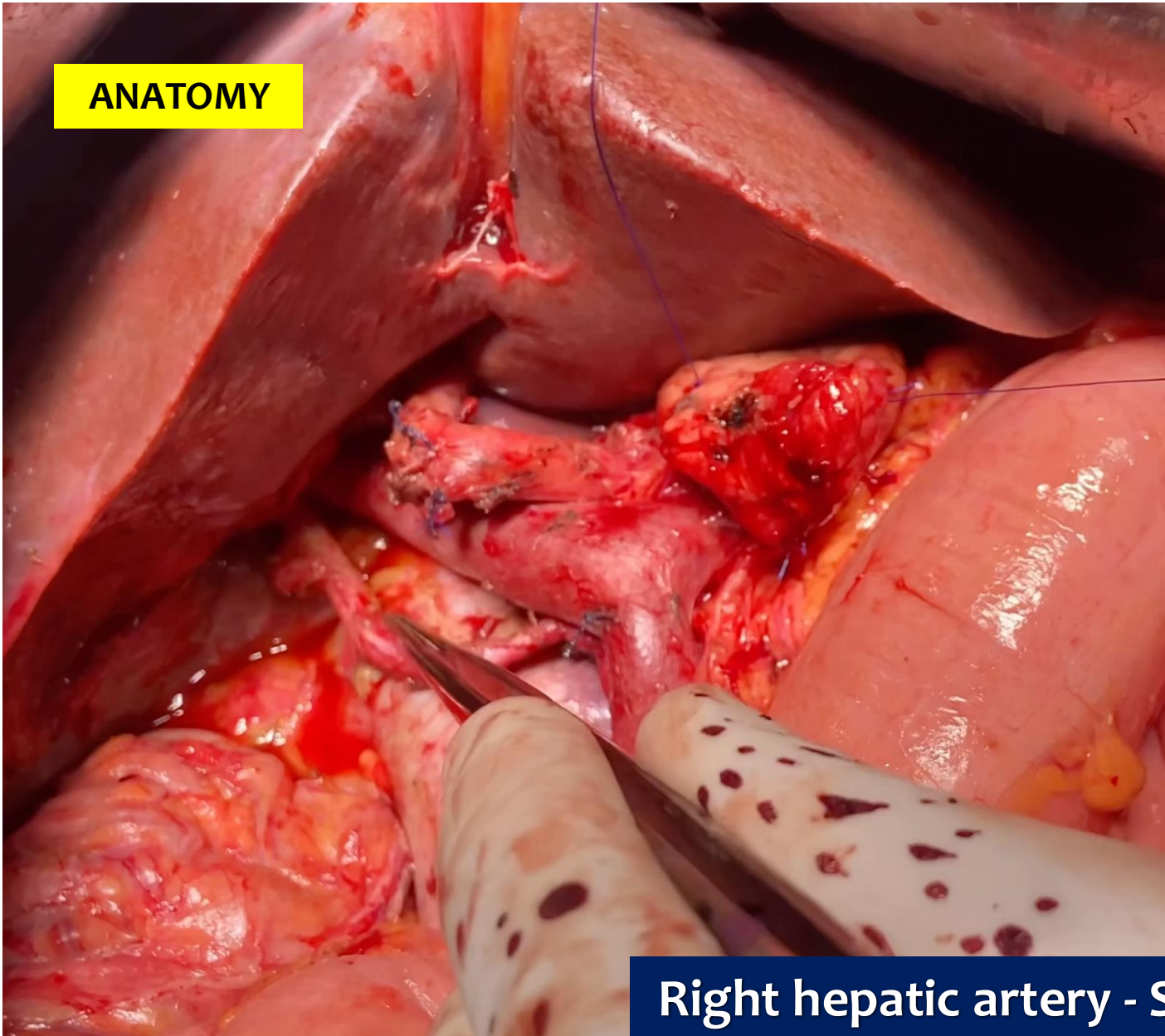


**FIRST JEJUNAL ARTERY**

# FIRST JEJUNAL ARTERY

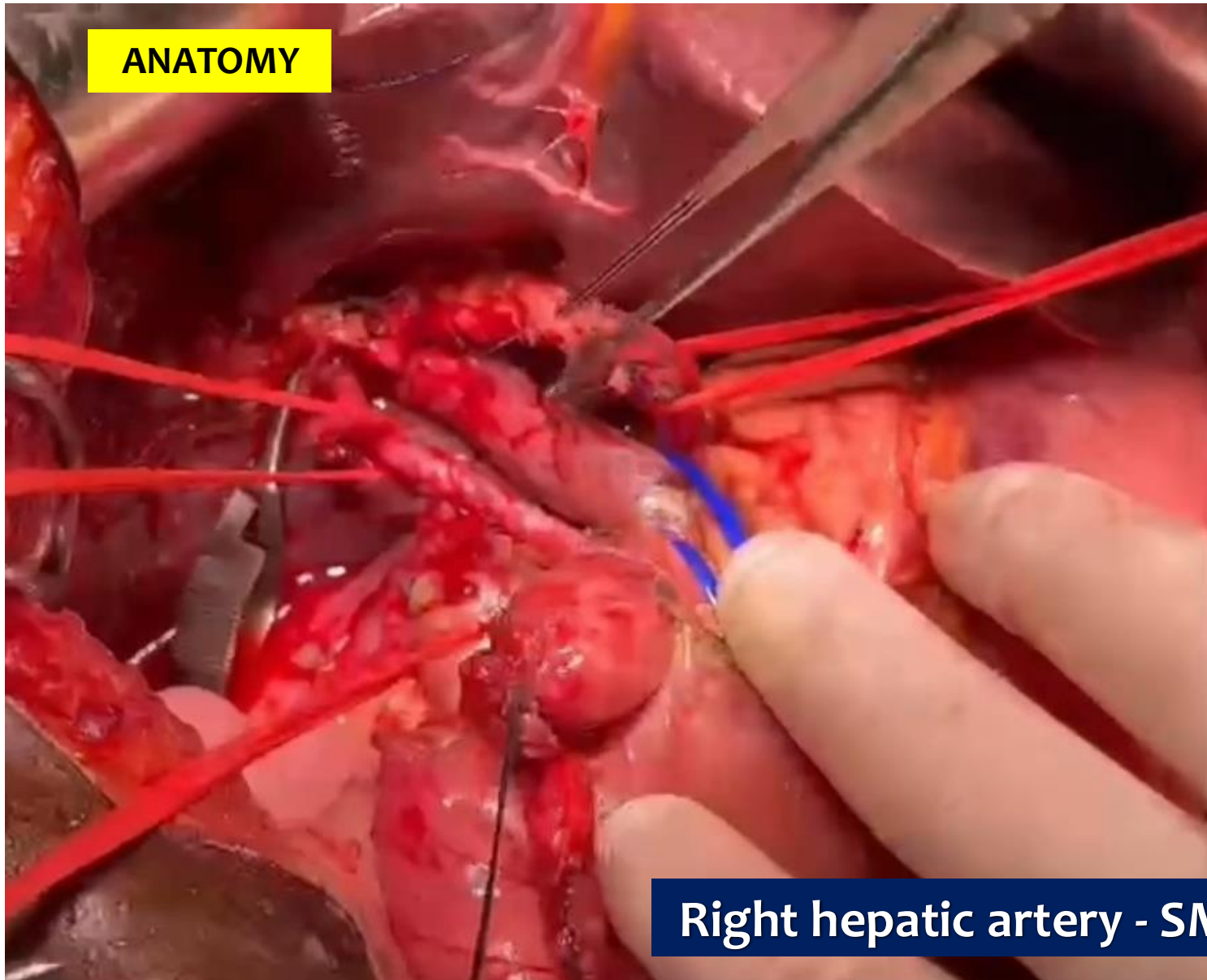


**ANATOMY**



**Right hepatic artery - SMA**

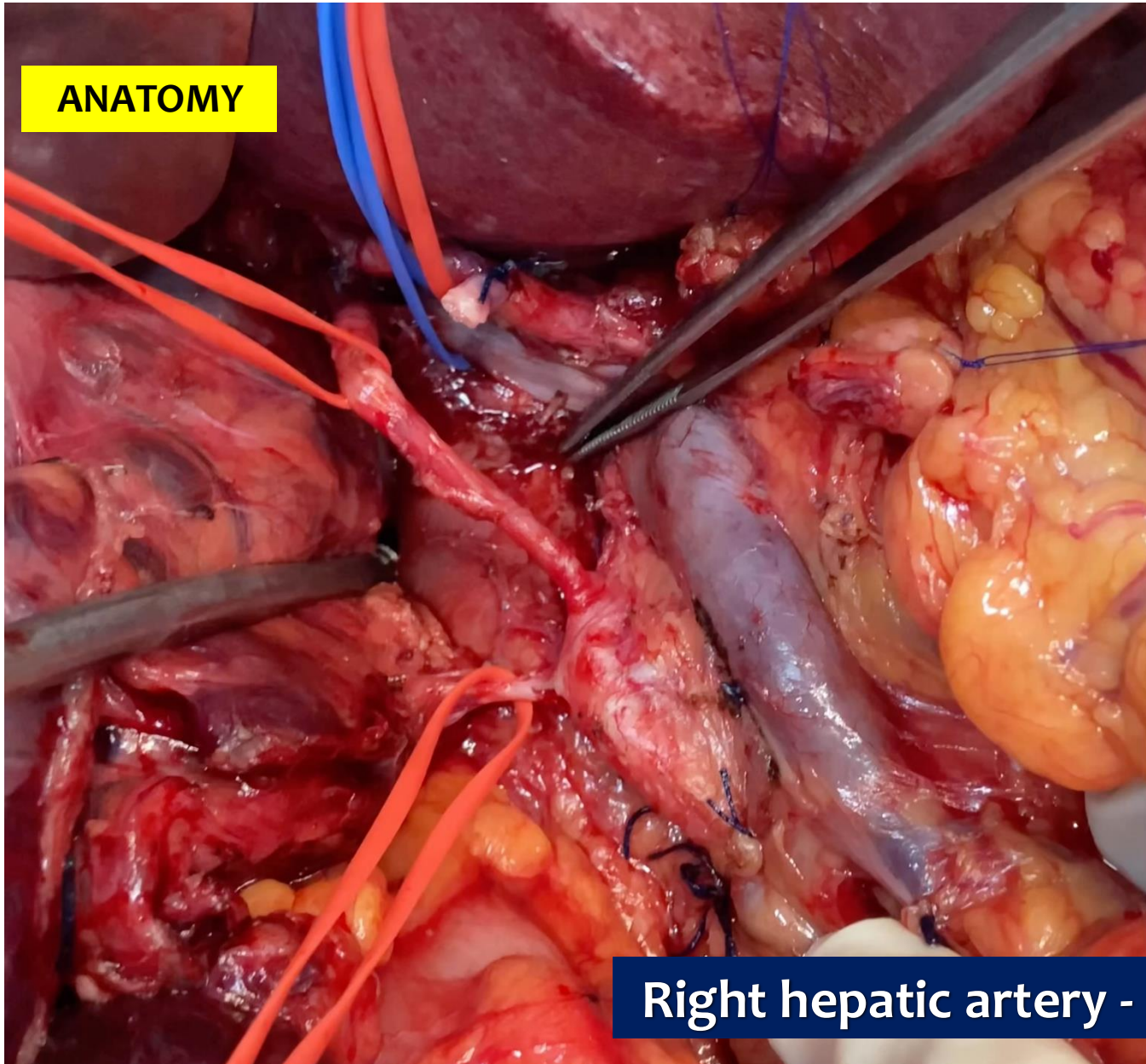
**ANATOMY**



**Right hepatic artery - SMA**

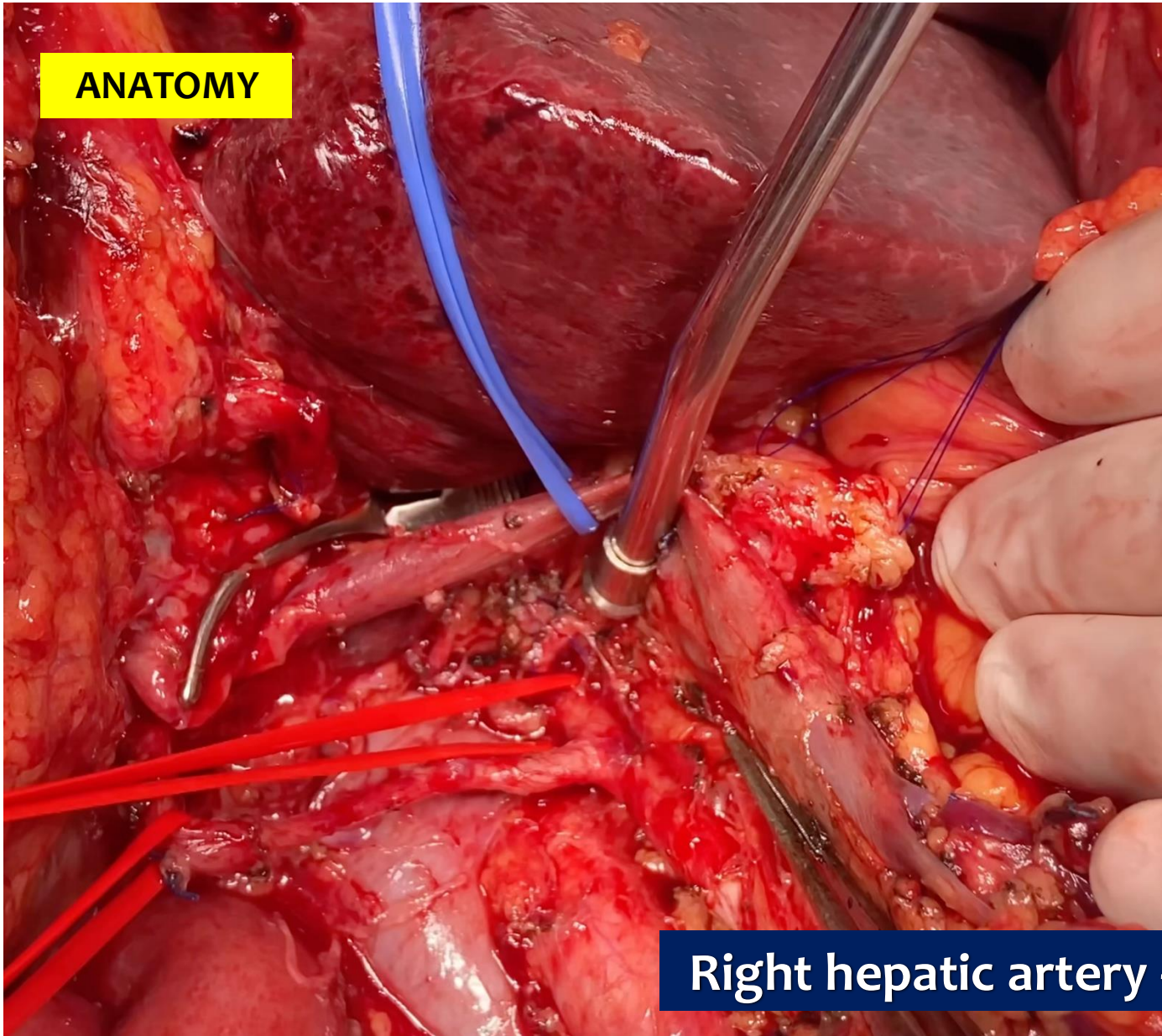


**ANATOMY**



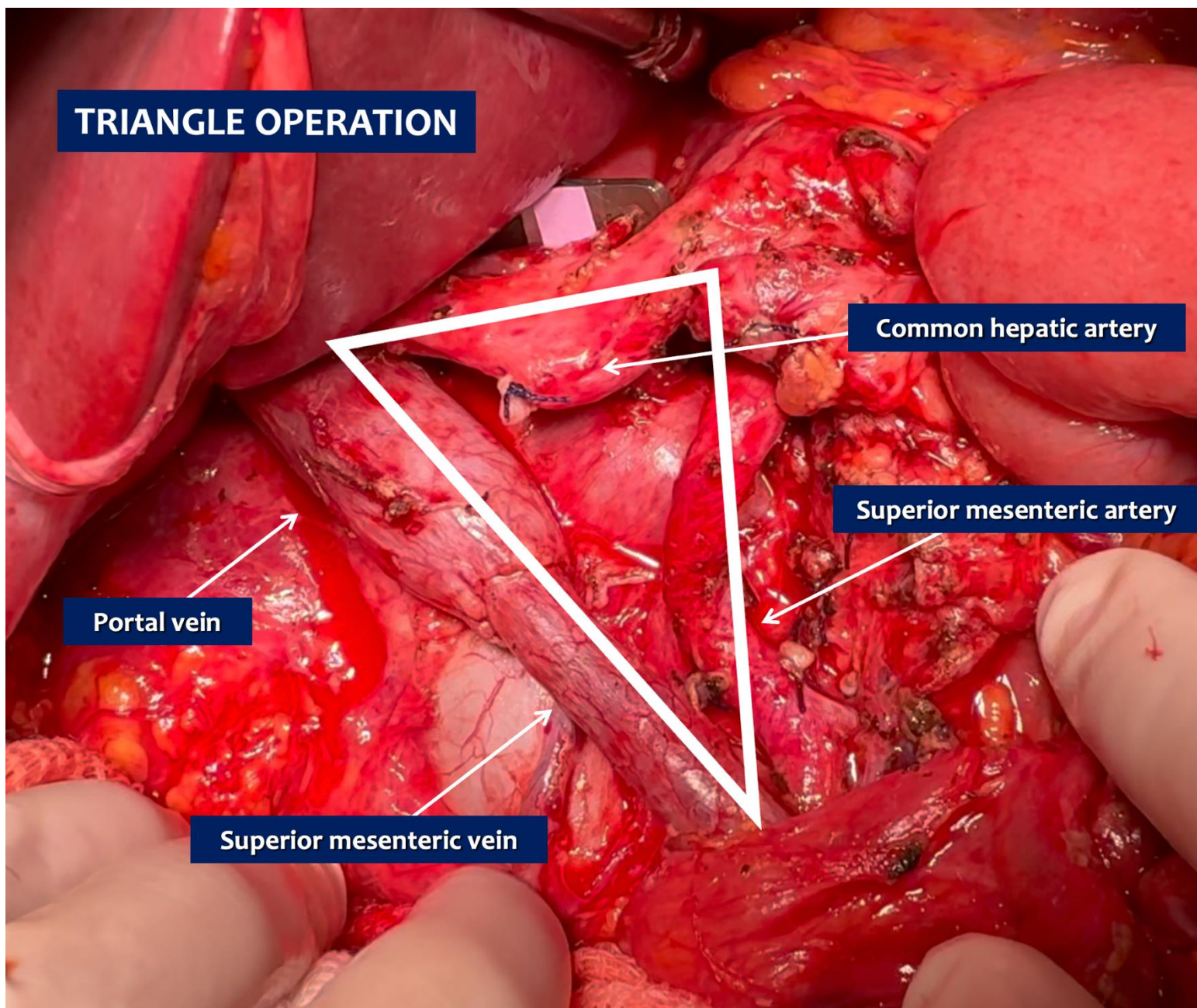
**Right hepatic artery - SMA**

**ANATOMY**



**Right hepatic artery - SMA**

# TRIANGLE OPERATION



Common hepatic artery

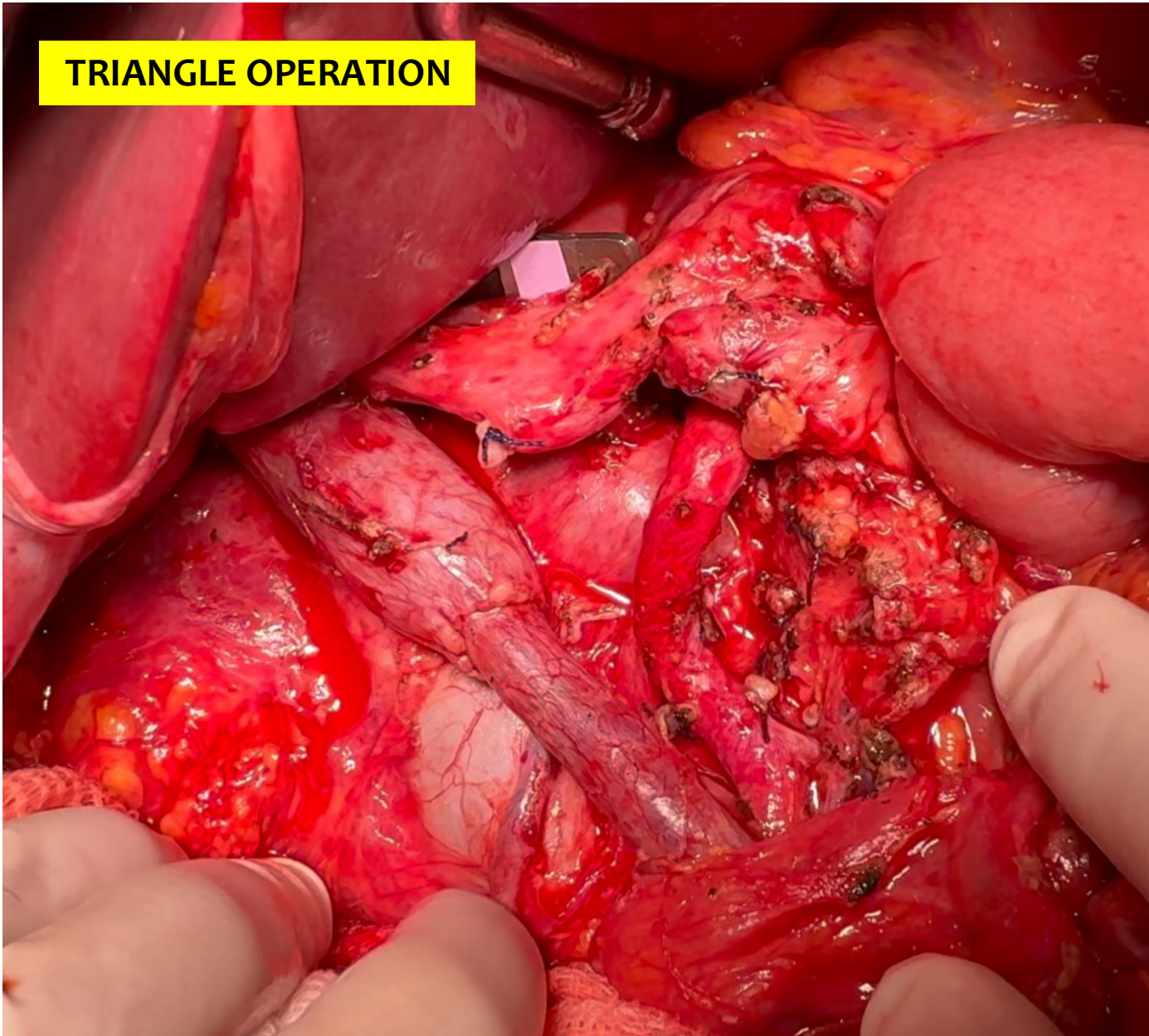
Superior mesenteric artery

Portal vein

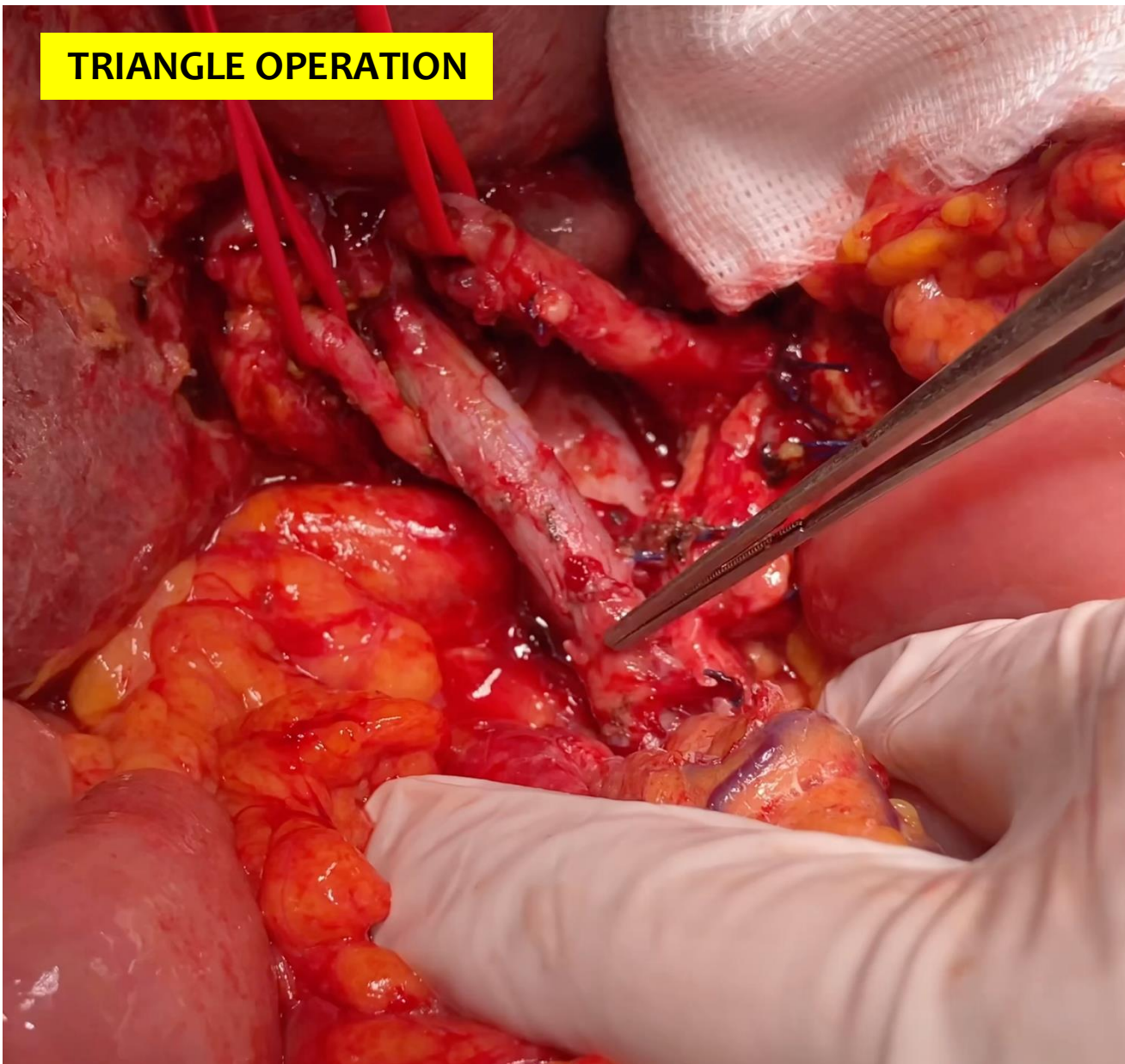
Superior mesenteric vein



## TRIANGLE OPERATION



## TRIANGLE OPERATION



# LYMPHADENECTOMY

□ Hepatoduodenal ligament  
12a, 12b1, 12b2, 12p, 12c

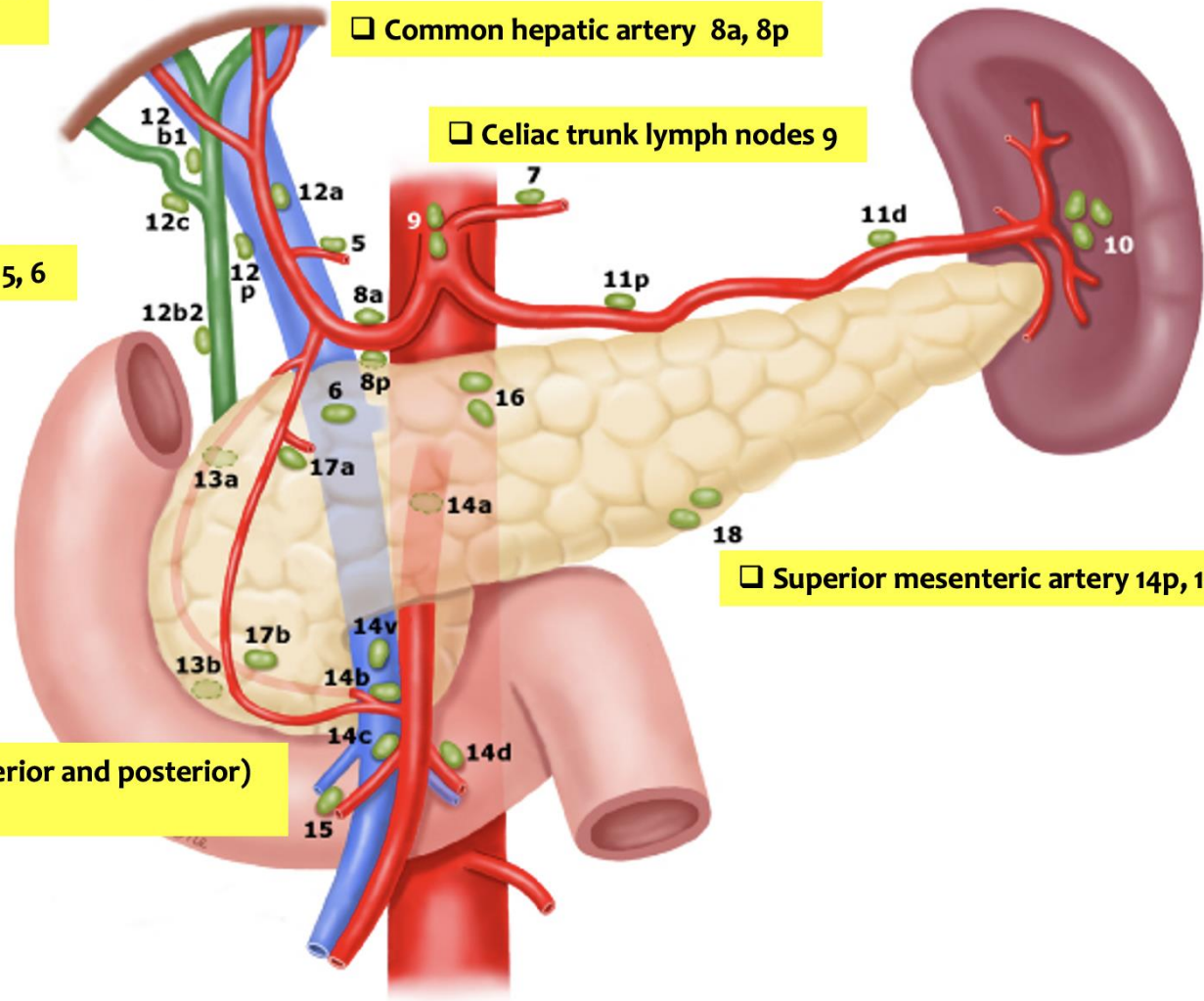
□ Common hepatic artery 8a, 8p

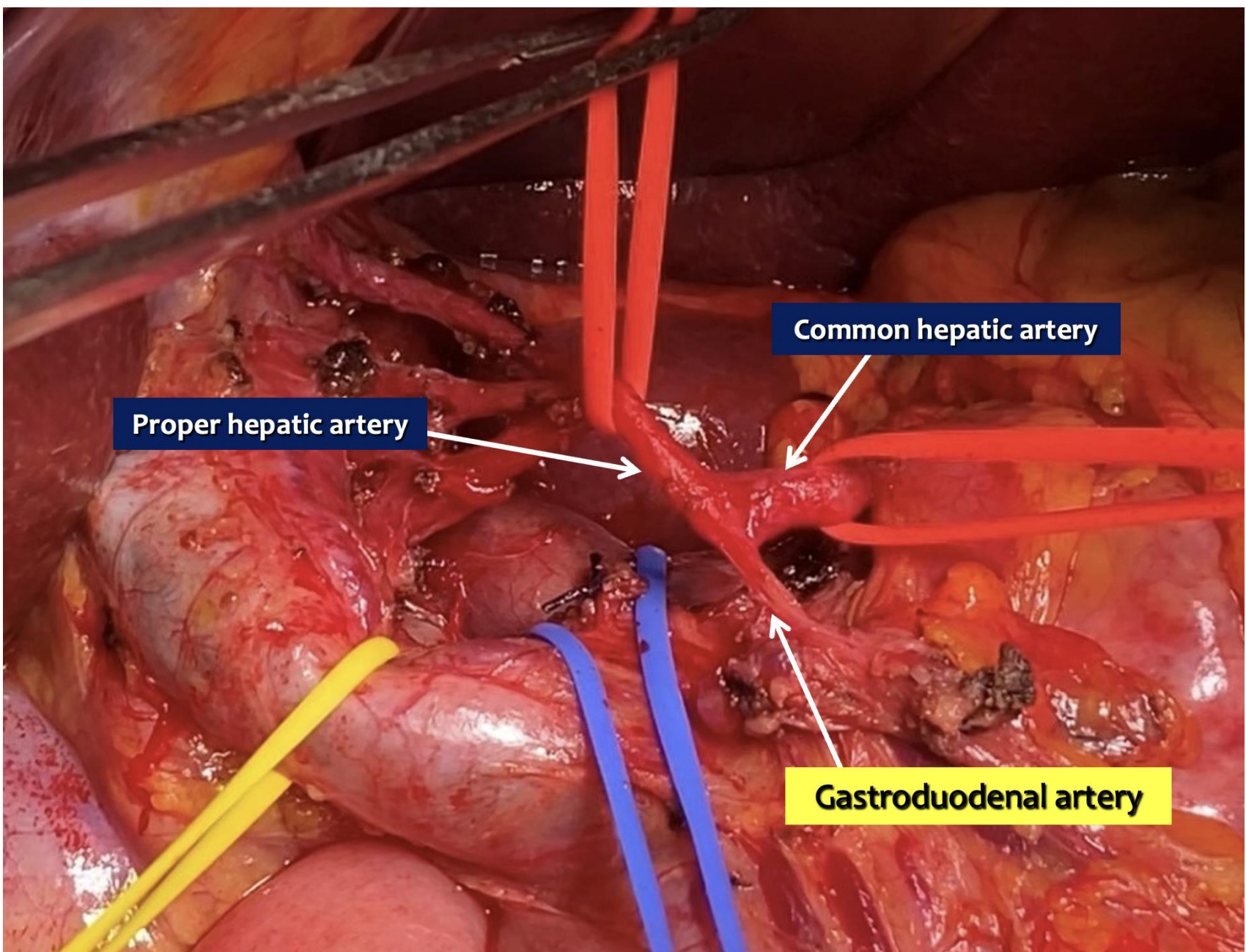
□ Celiac trunk lymph nodes 9

□ Pyloric 5, 6

□ Superior mesenteric artery 14p, 14d

□ Pancreatoduodenal (anterior and posterior)  
13a, 13b, 17a, 17b






**Proper hepatic artery**

**Common hepatic artery**

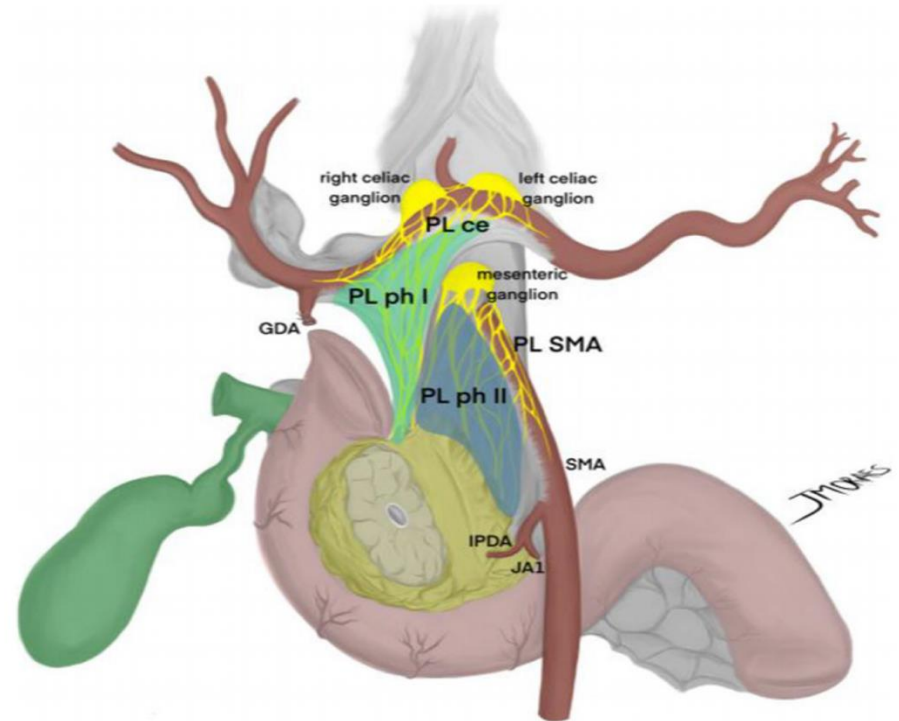
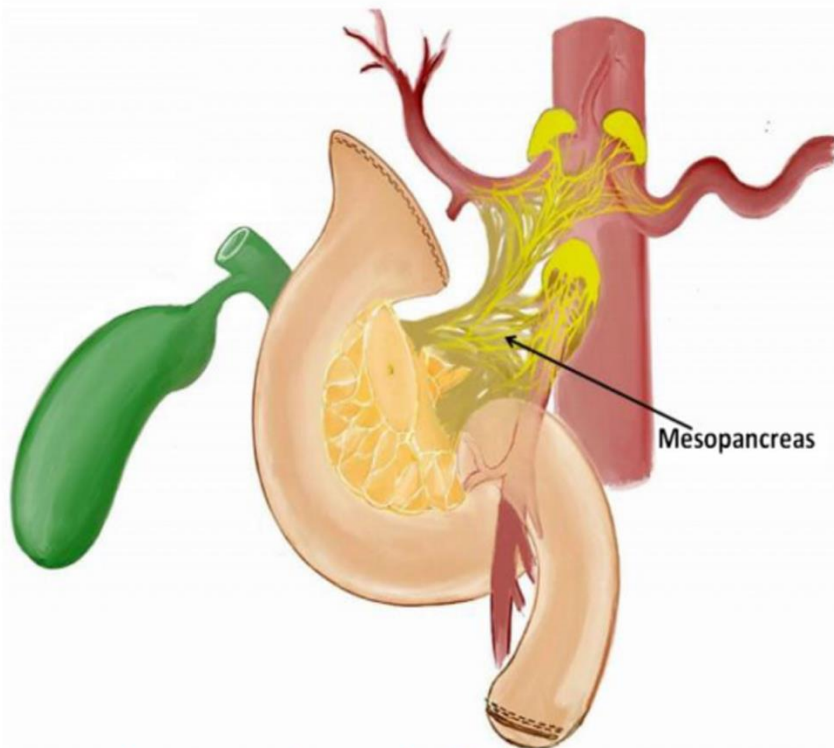
**Gastroduodenal artery**



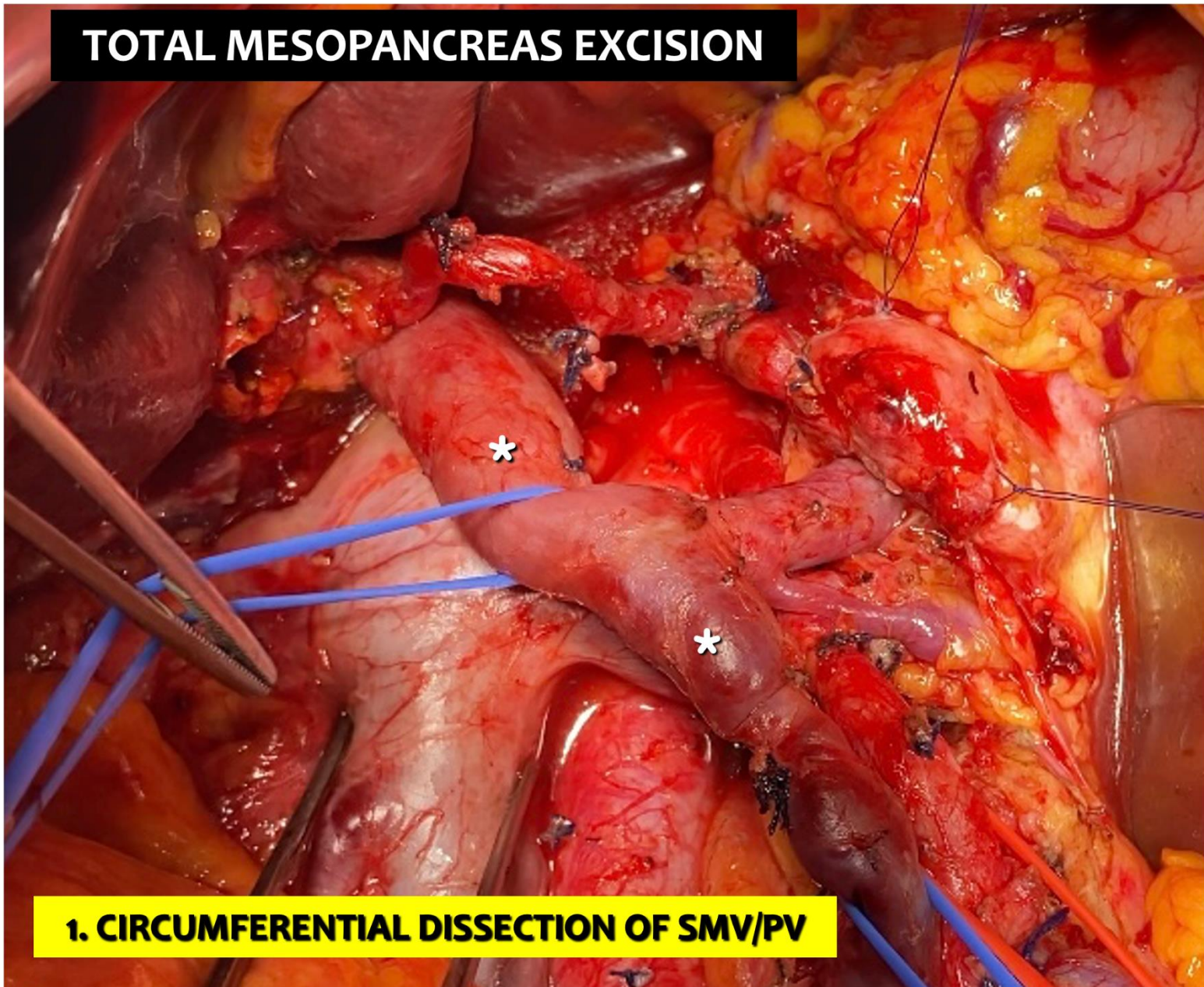
## What do surgeons need to know about the mesopancreas

Eduardo de Souza M. Fernandes<sup>1,2</sup> · Oliver Strobel<sup>3,4</sup> · Camila Girão<sup>1,2</sup> · Jose Maria A. Moraes-Junior<sup>5,6</sup> · Orlando Jorge M. Torres<sup>5,6</sup> 

# TOTAL MESOPANCREAS EXCISION

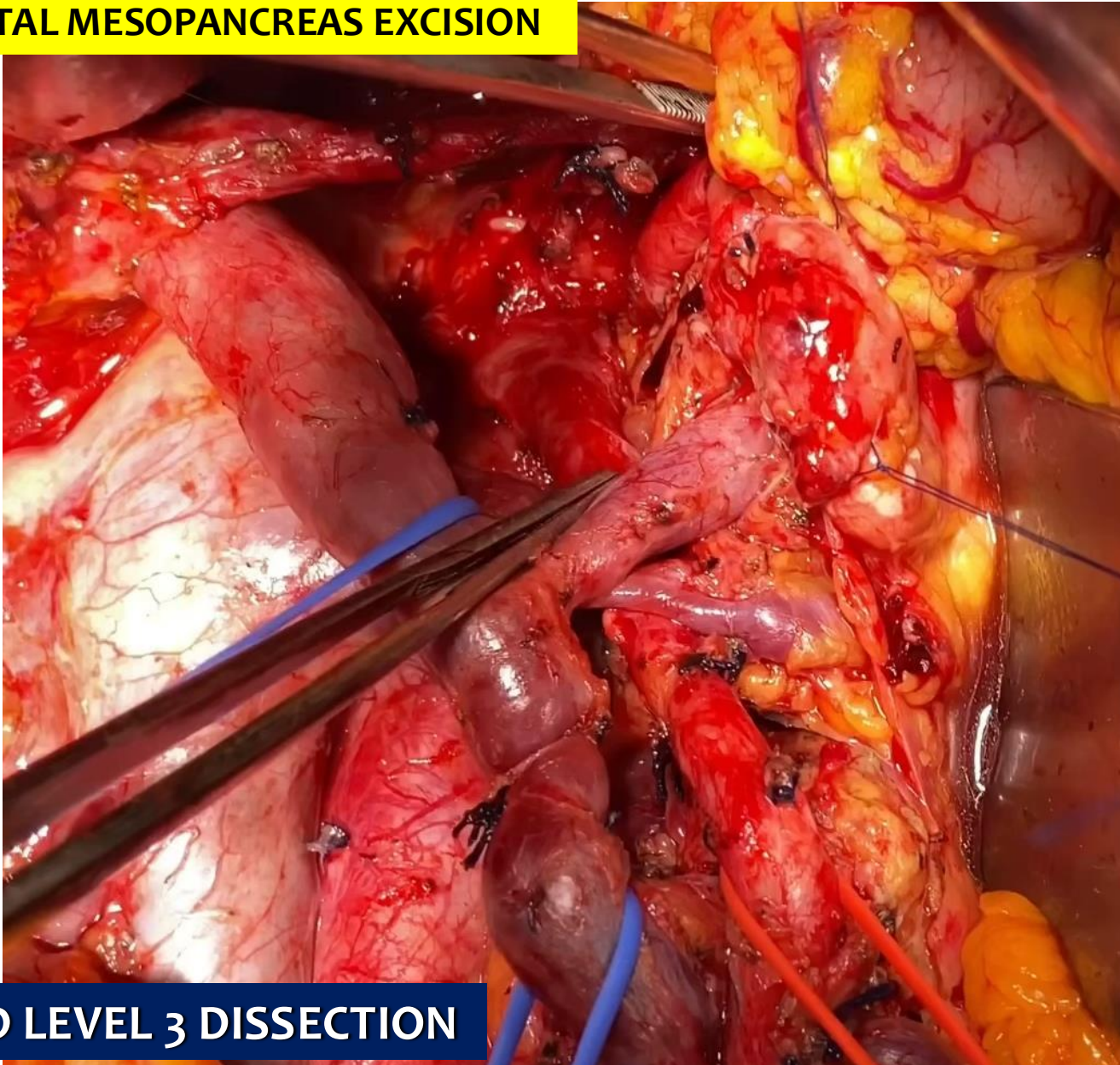


# TOTAL MESOPANCREAS EXCISION



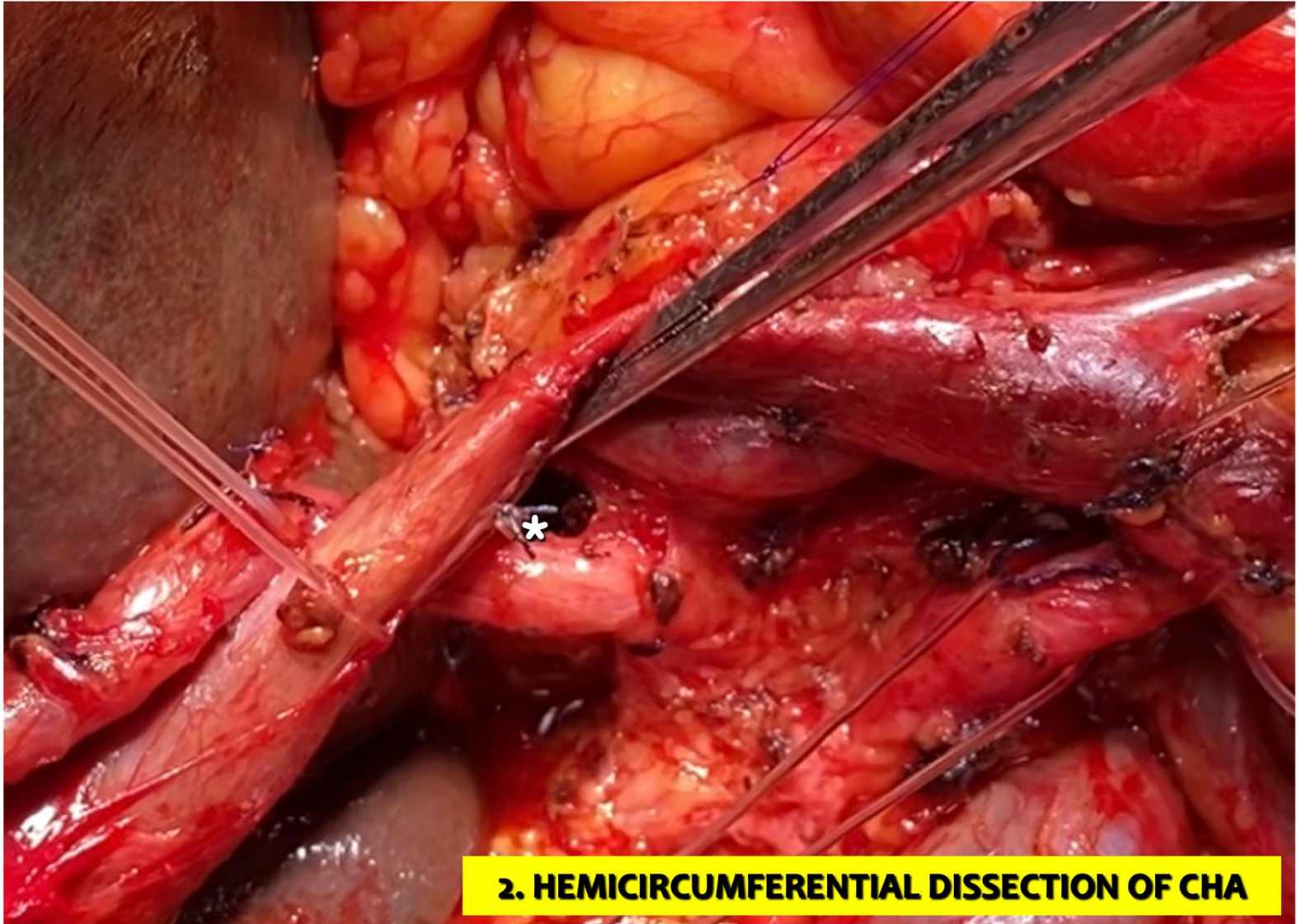
**1. CIRCUMFERENTIAL DISSECTION OF SMV/PV**

# TOTAL MESOPANCREAS EXCISION



EXTENDED LEVEL 3 DISSECTION





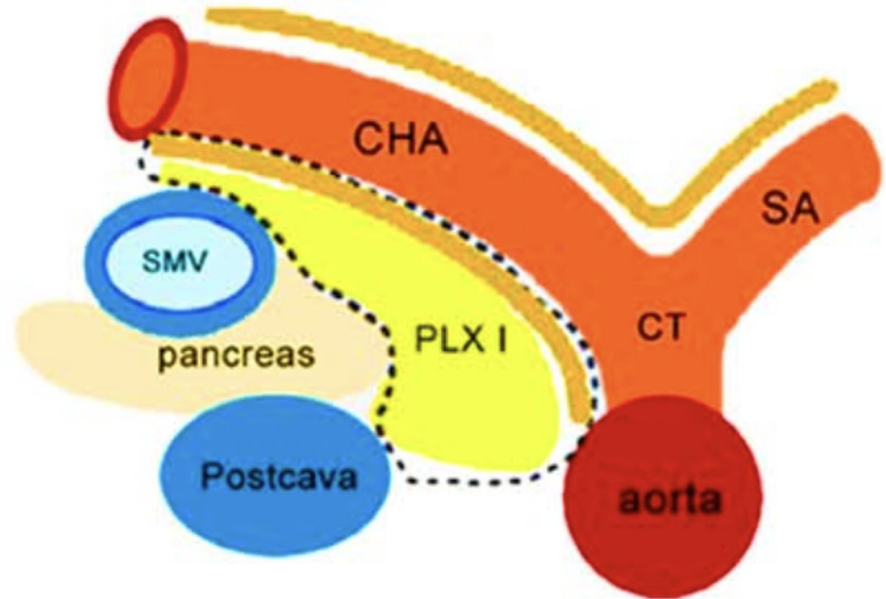
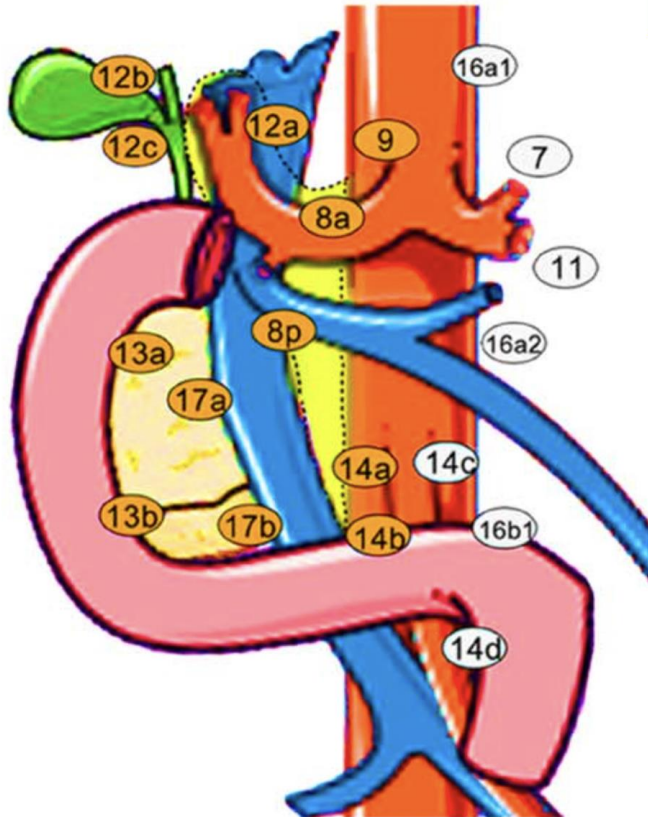
**2. HEMICIRCUMFERENTIAL DISSECTION OF CHA**

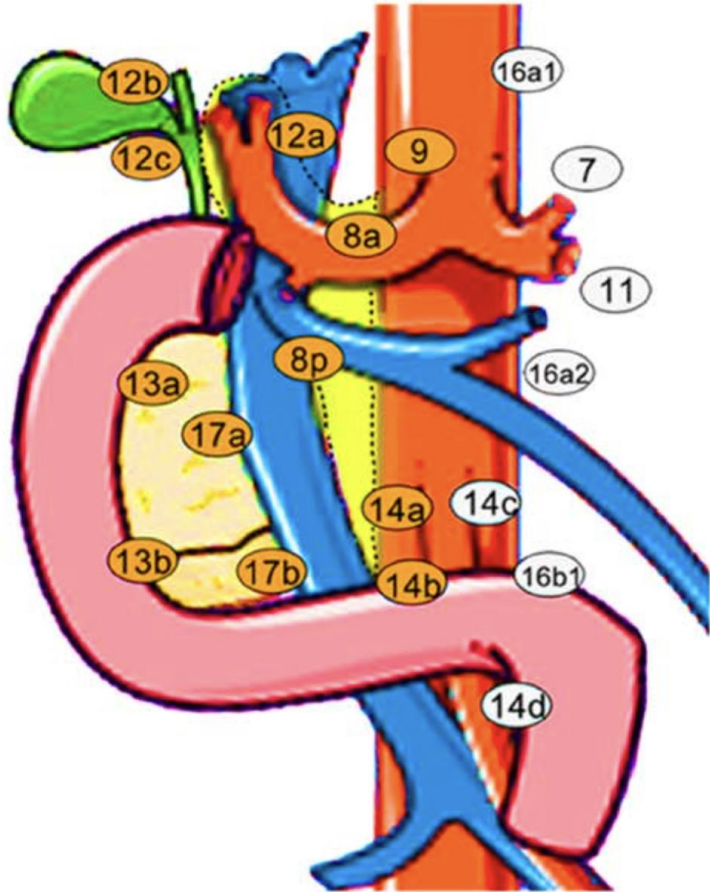


□ Common hepatic artery lymph nodes 8a, 8p

□ 8a

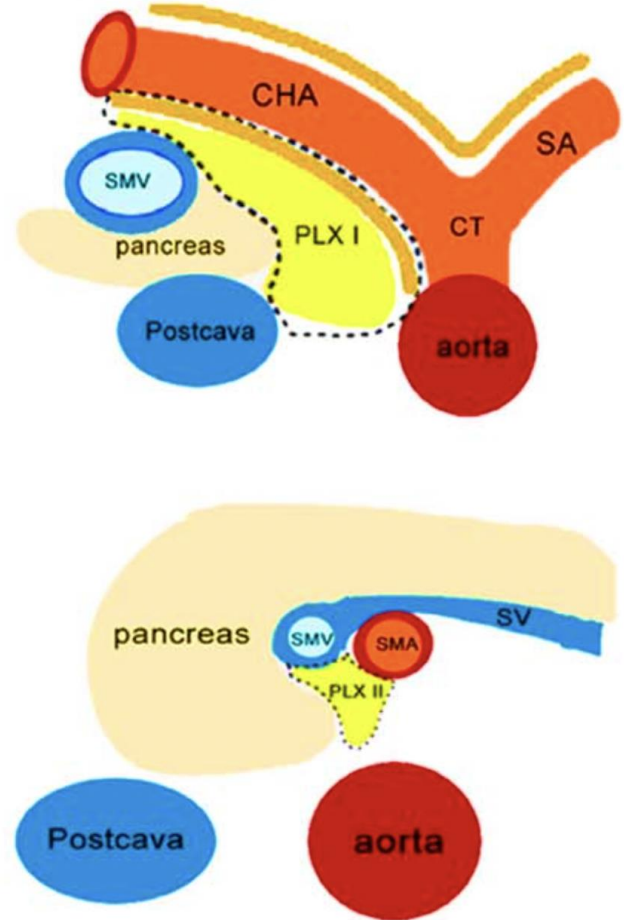
□ 8p

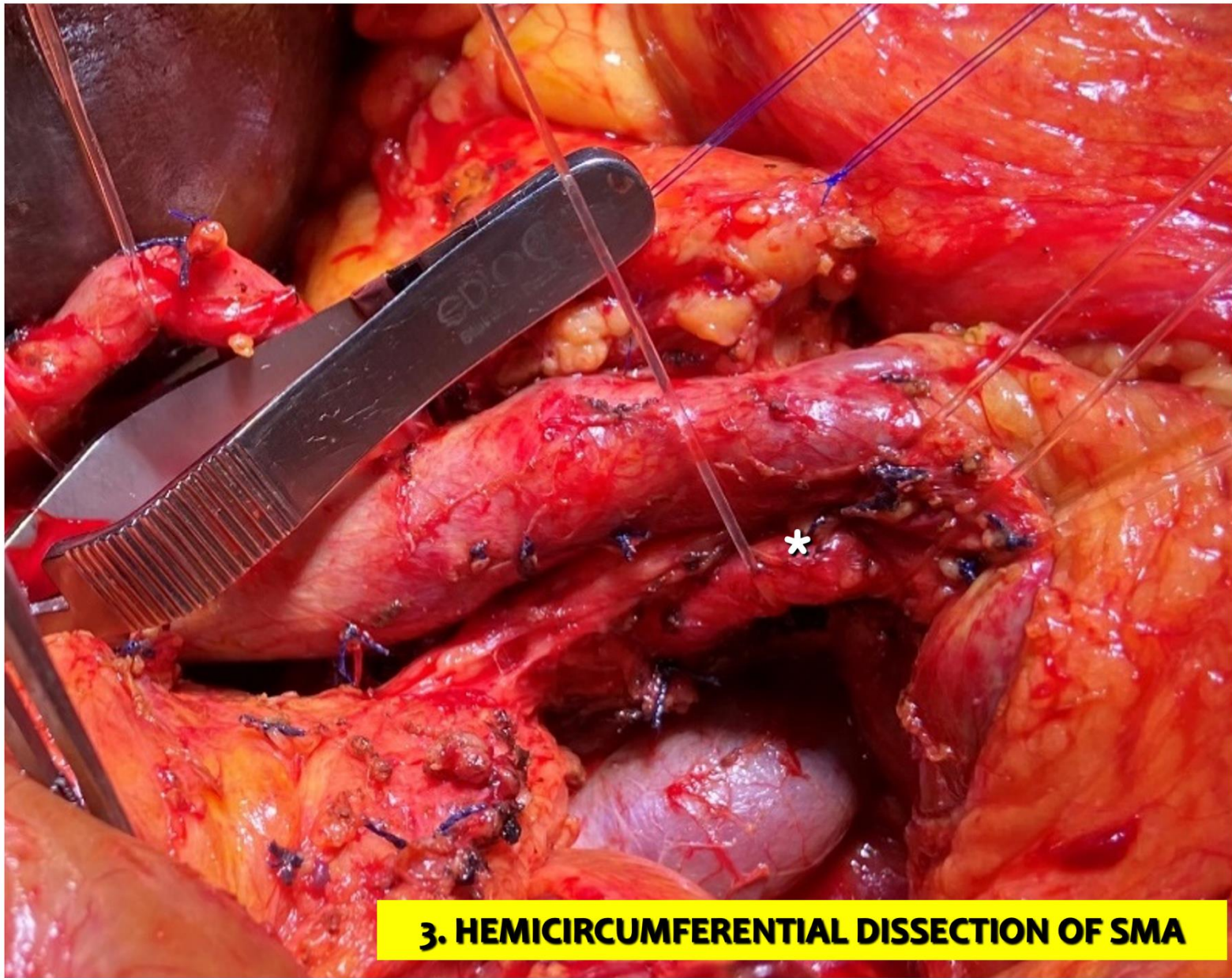




□ 9

□ Celiac trunk lymph nodes 9



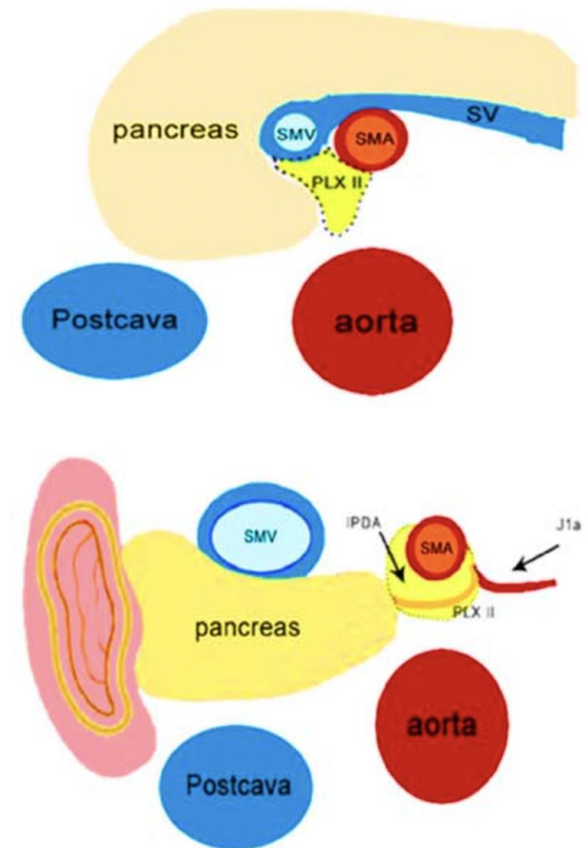
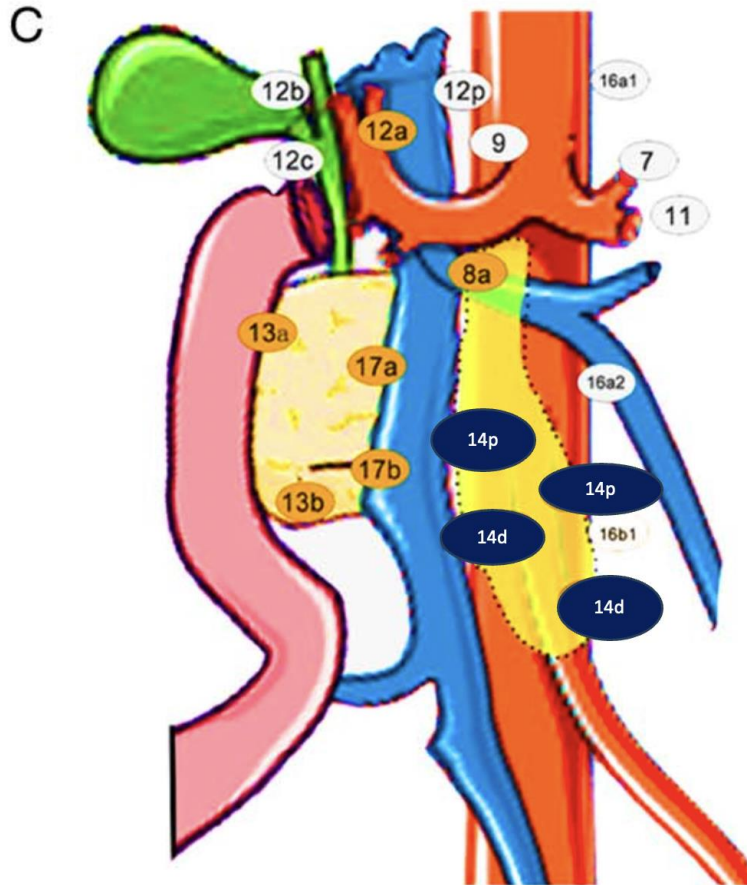


### 3. HEMICIRCUMFERENTIAL DISSECTION OF SMA

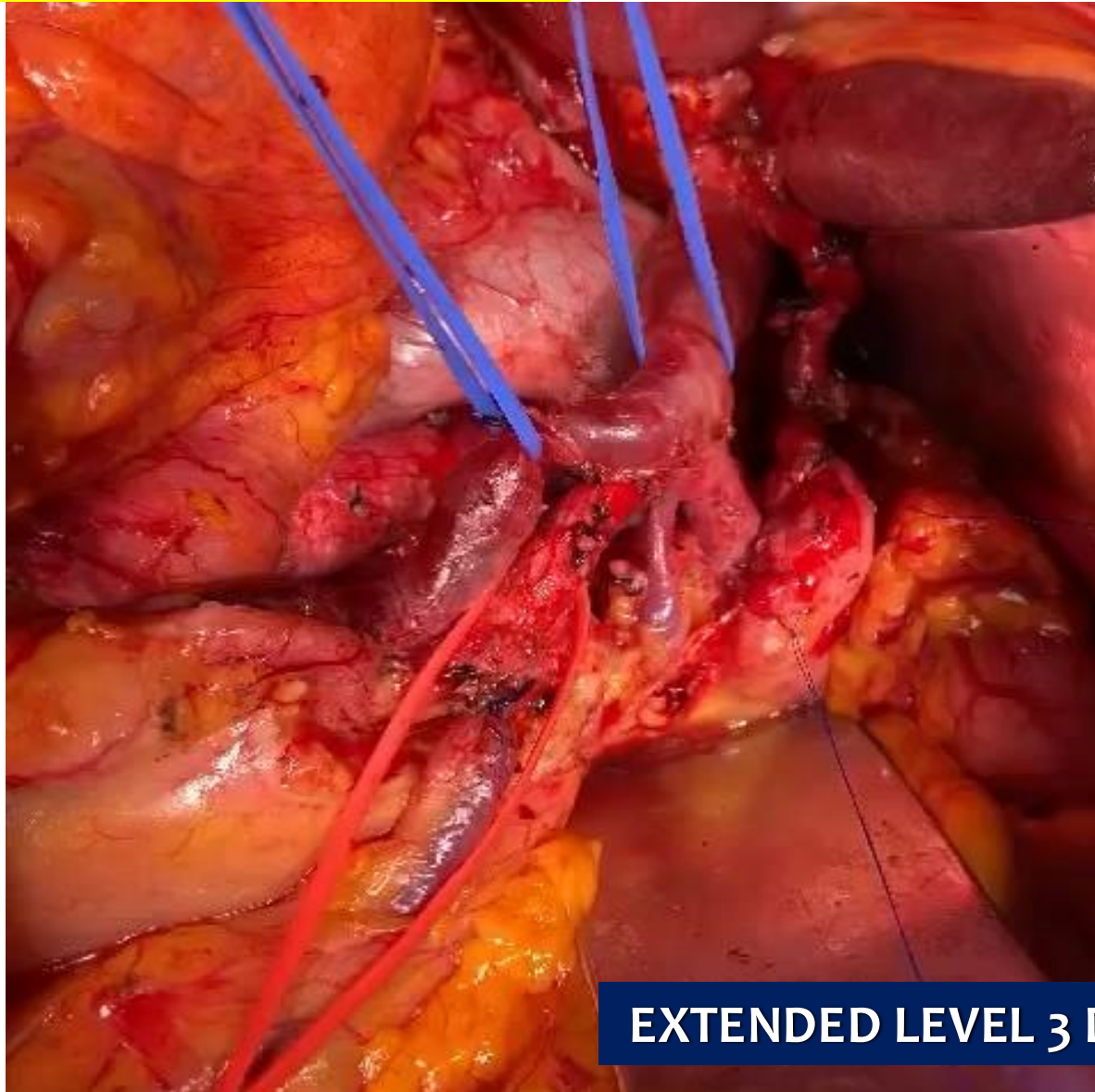# SUPERIOR MESENTERIC ARTERY LYMPH NODES

□14p

□14d

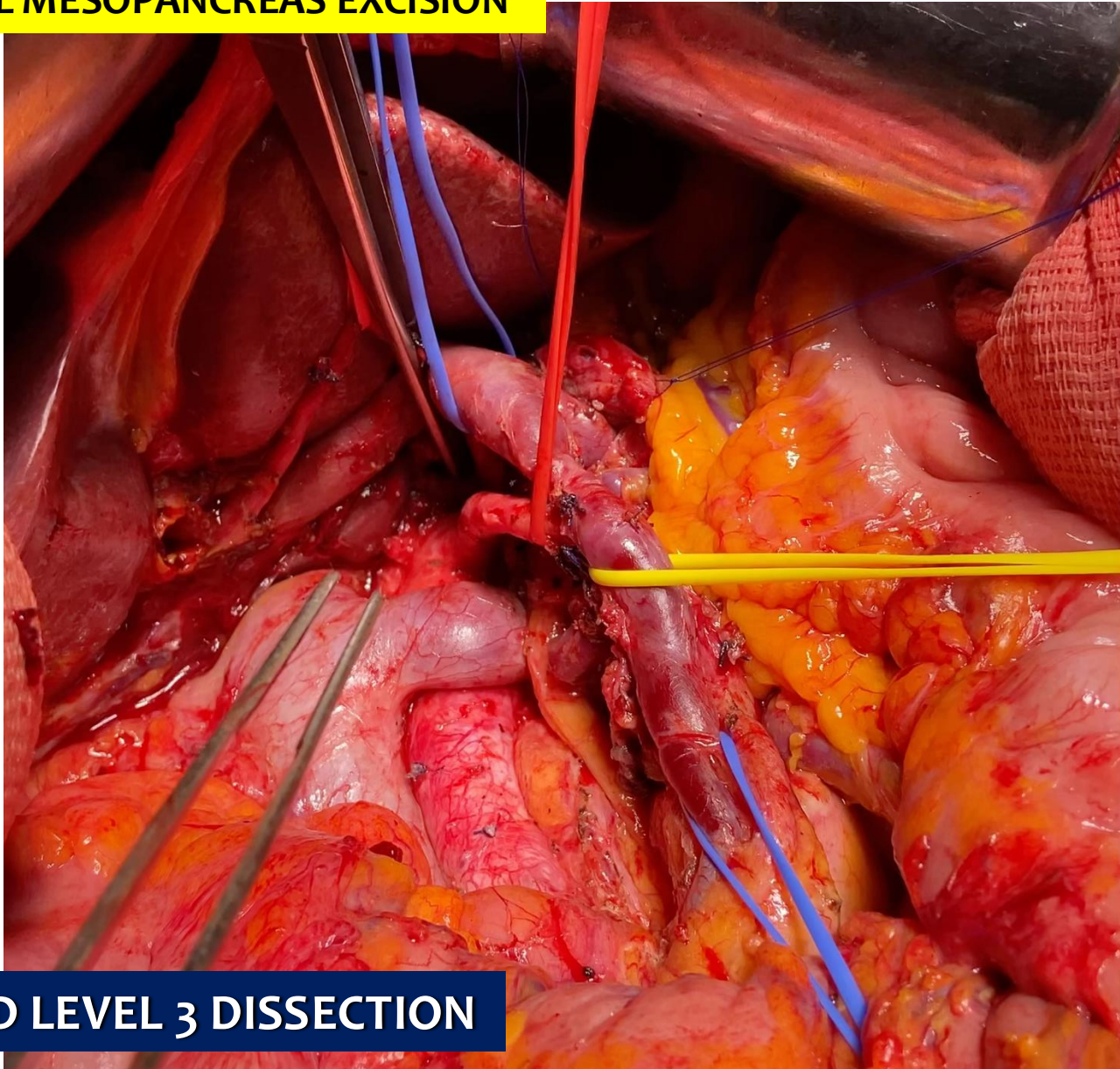


# TOTAL MESOPANCREAS EXCISION



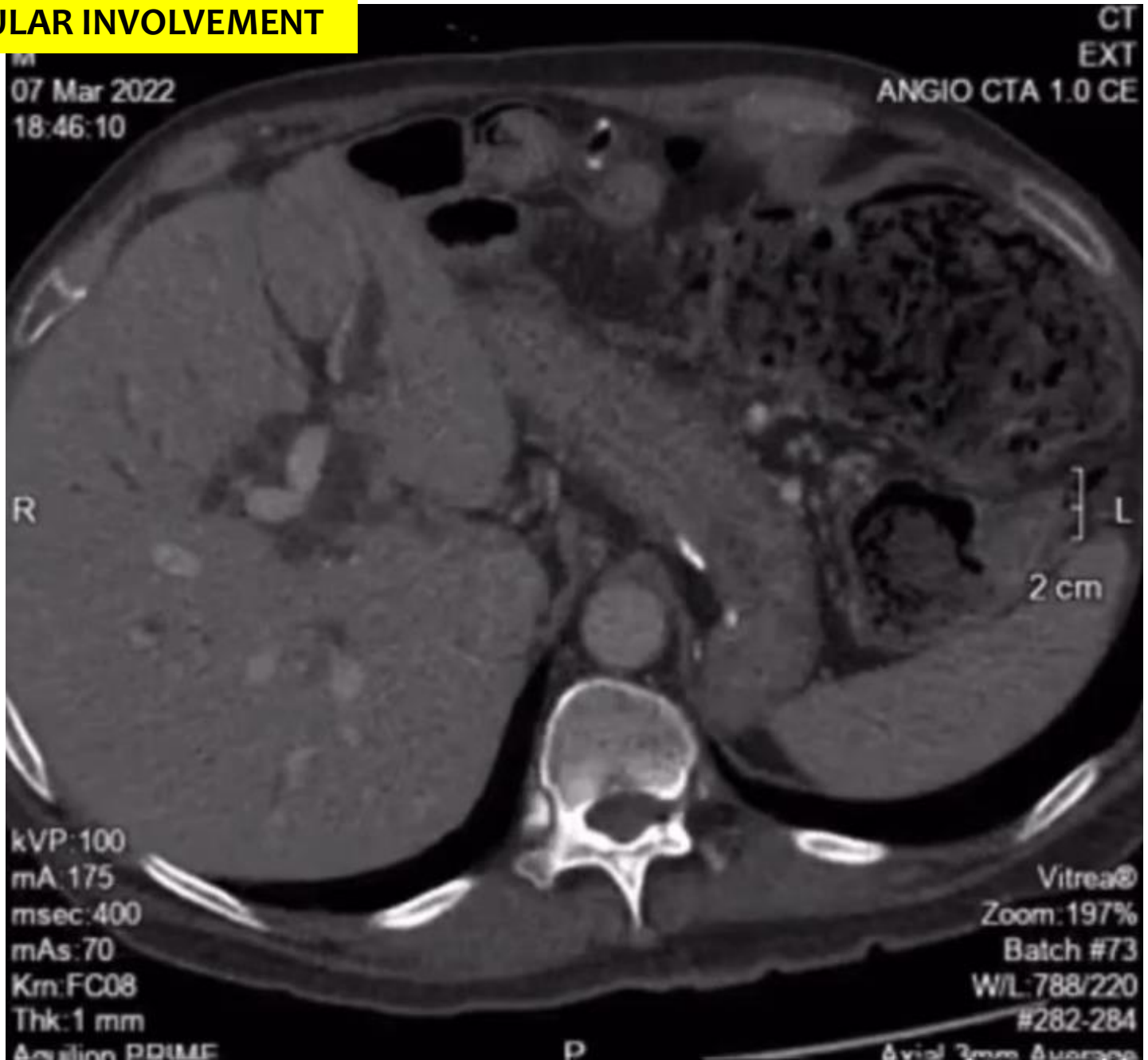
**EXTENDED LEVEL 3 DISSECTION**

# TOTAL MESOPANCREAS EXCISION



**EXTENDED LEVEL 3 DISSECTION**

# VASCULAR INVOLVEMENT



M  
07 Mar 2022  
18:46:10

EX  
ANGIO CTA 1.0 C

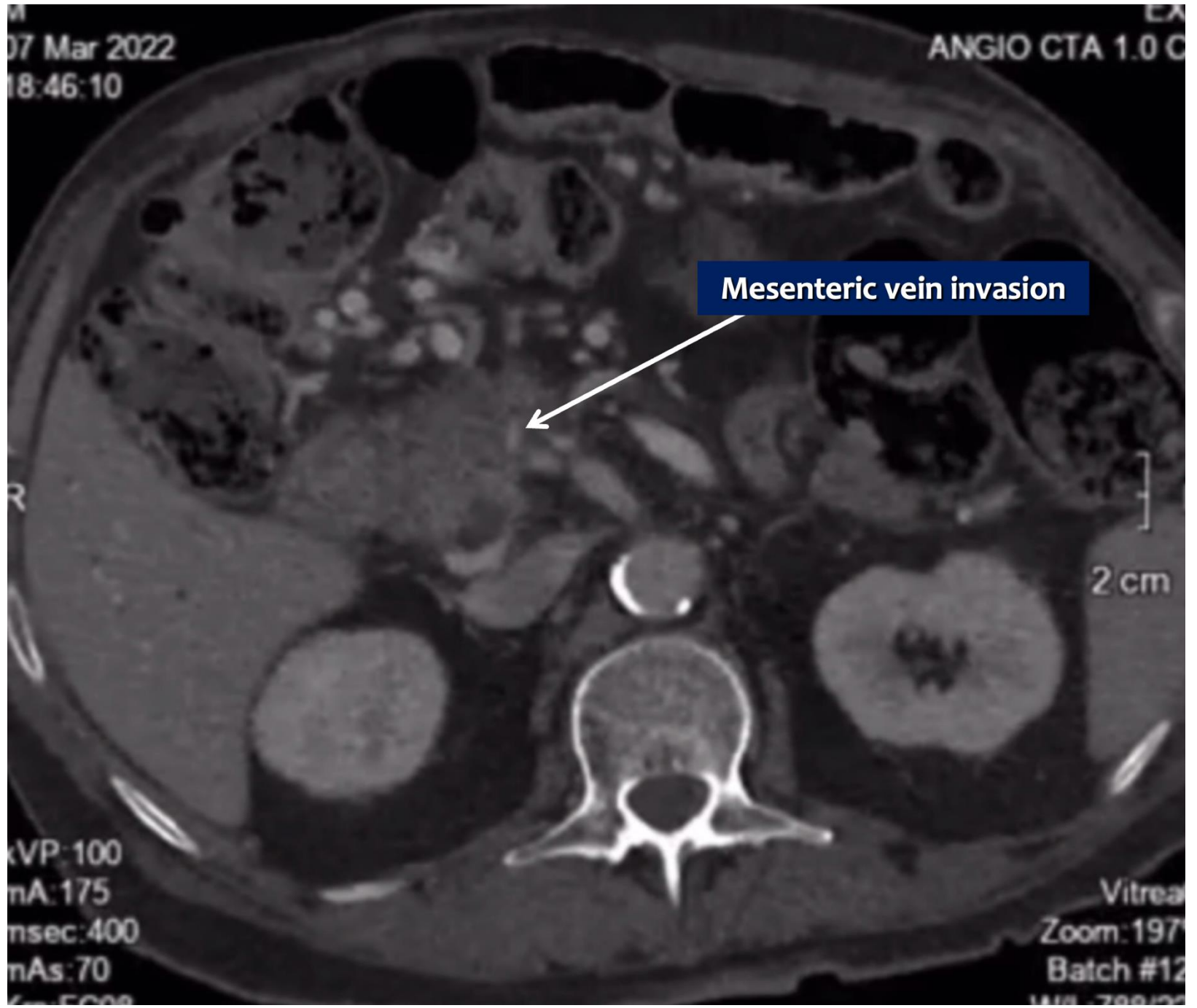
Mesenteric vein invasion



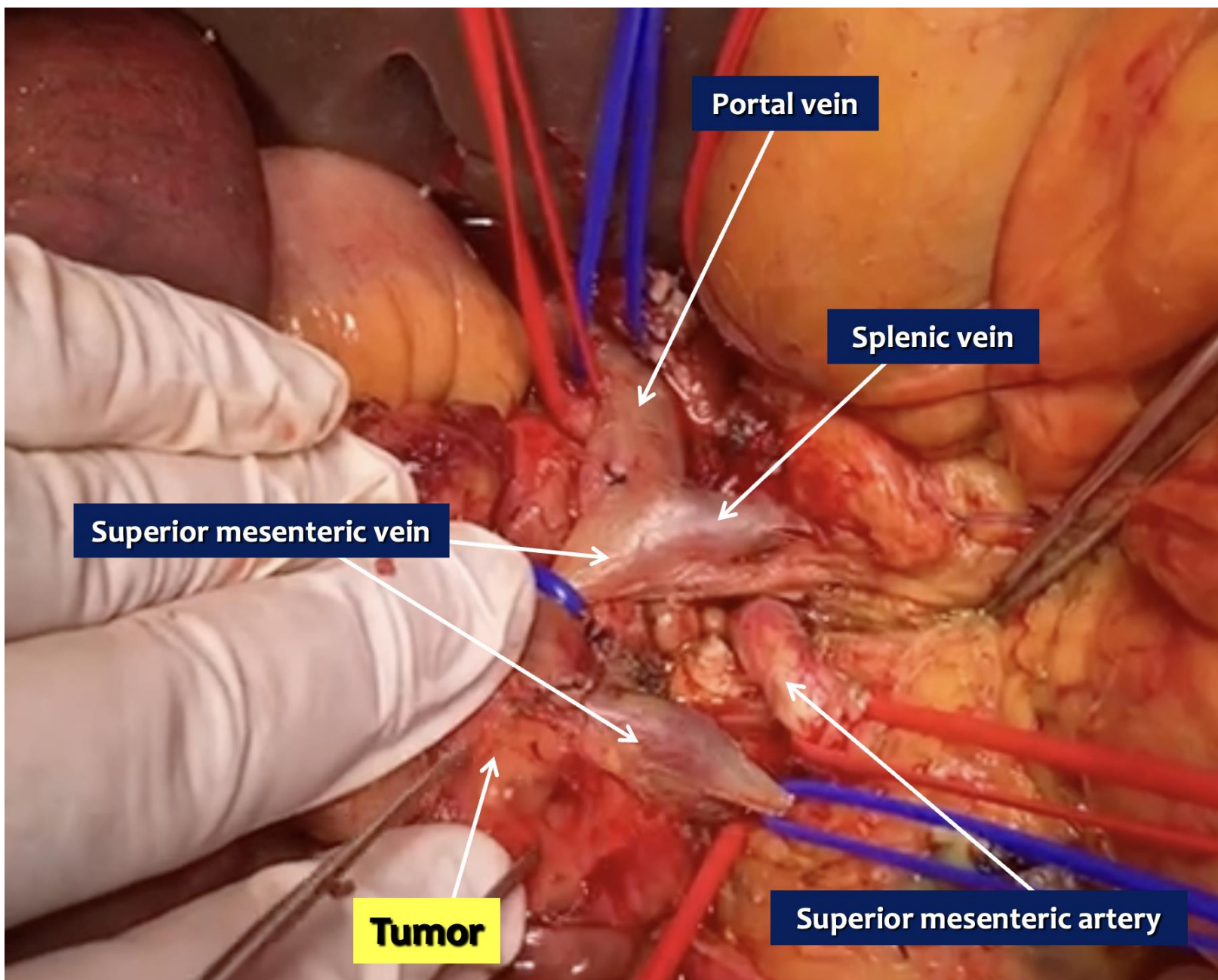
2 cm

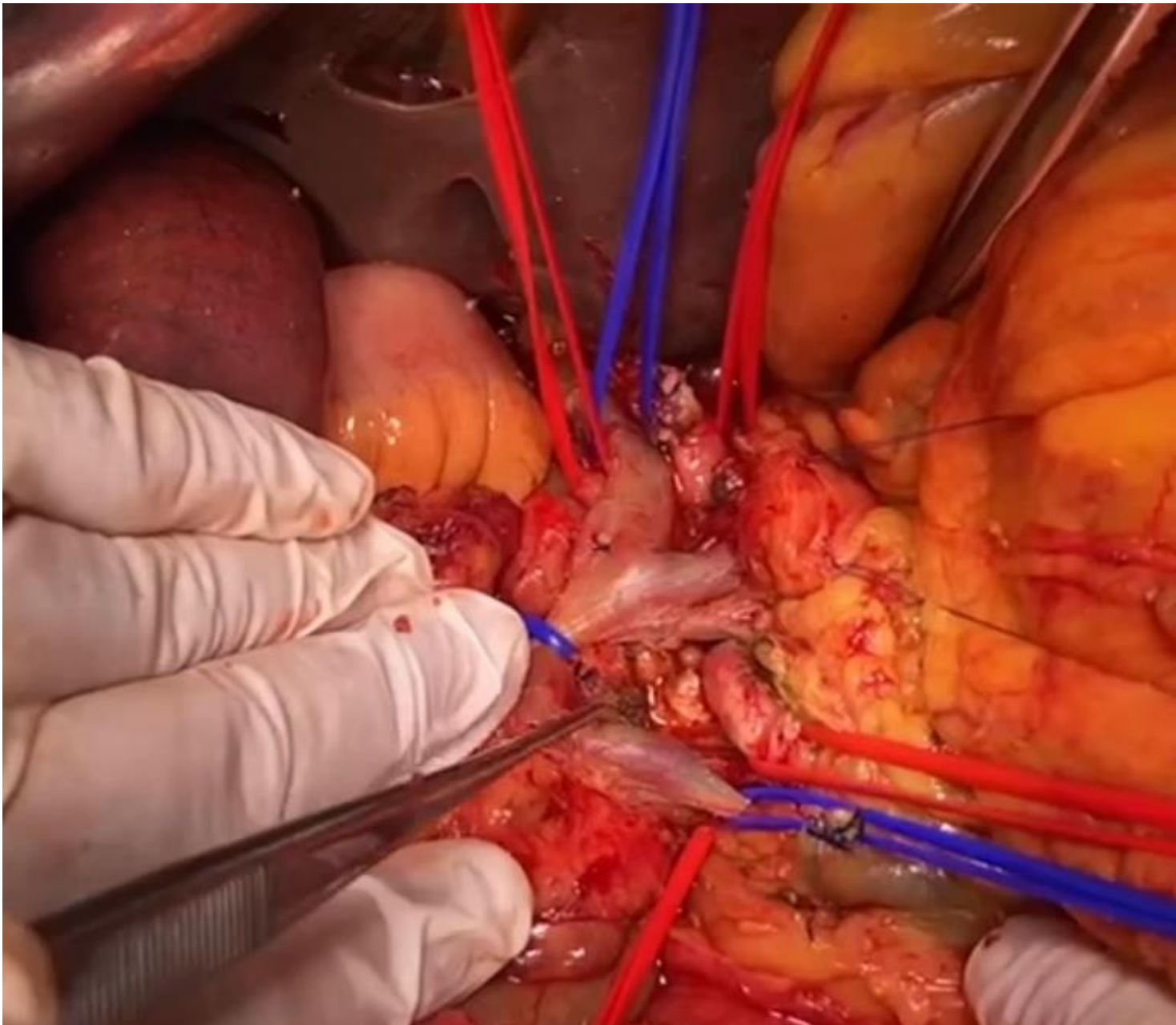
kVP: 100  
mA: 175  
msec: 400  
mAs: 70  
6m-FC00

Vitreal  
Zoom: 197  
Batch #12  
MIP: 788/200

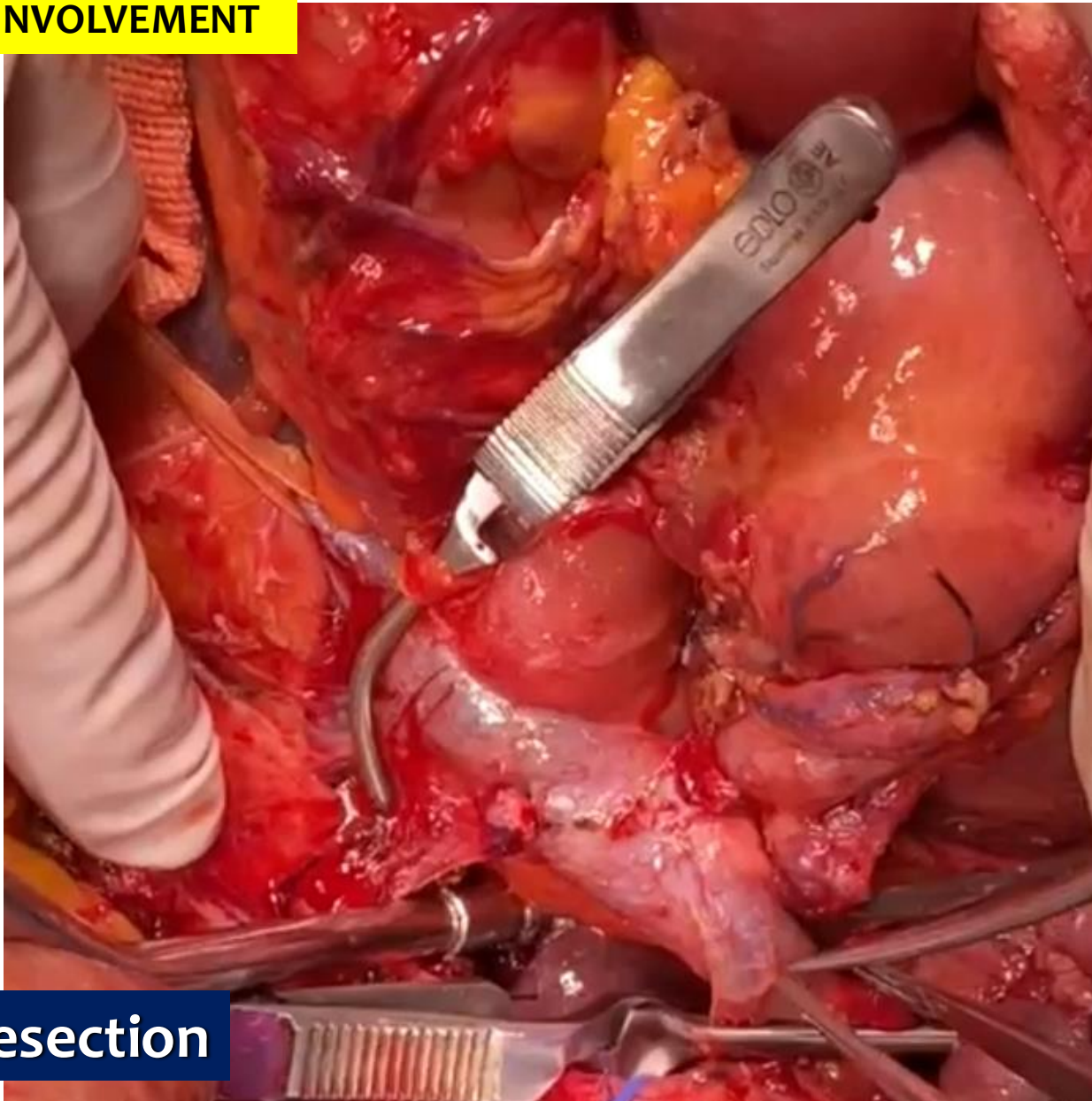






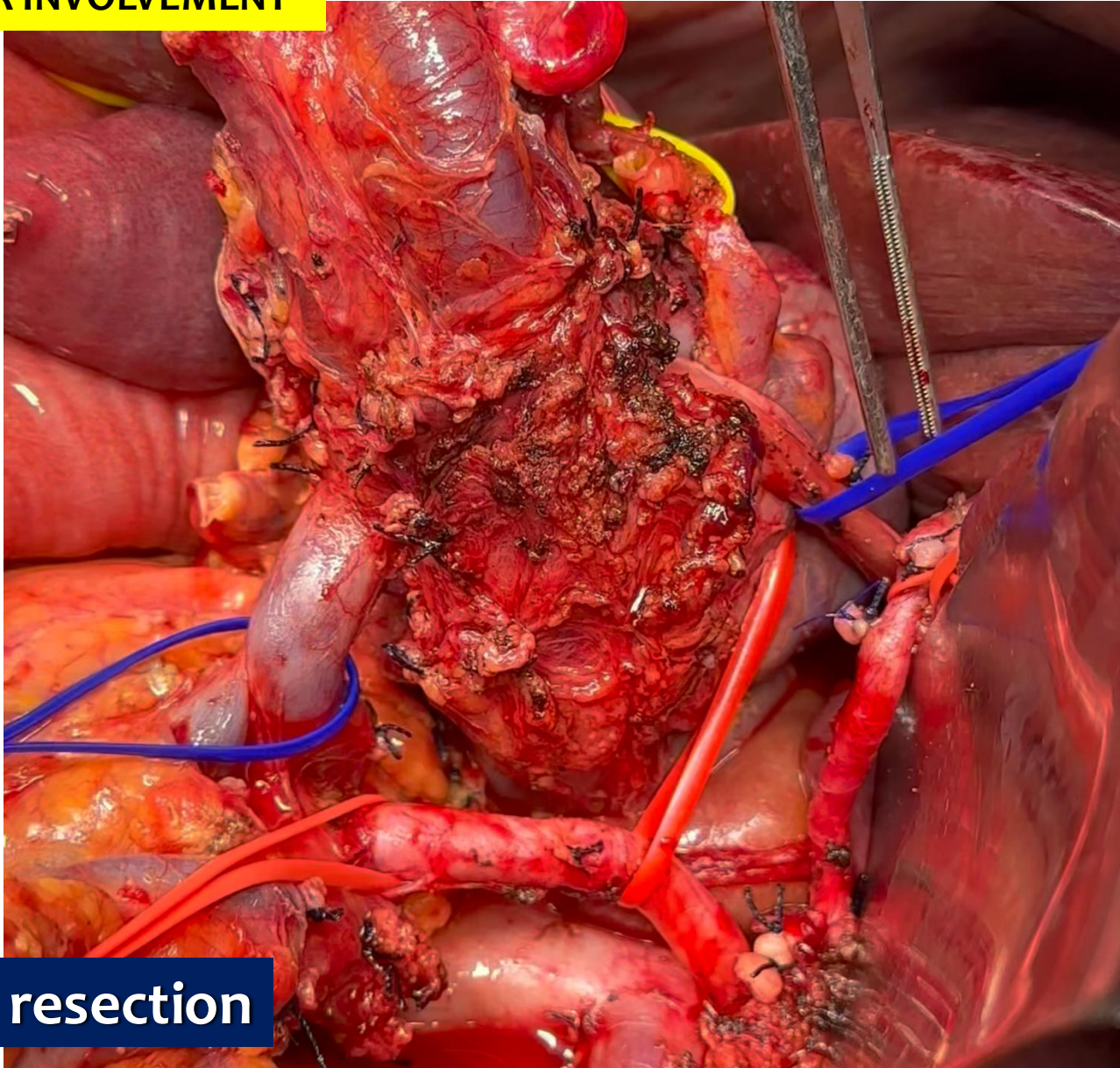


## VASCULAR INVOLVEMENT



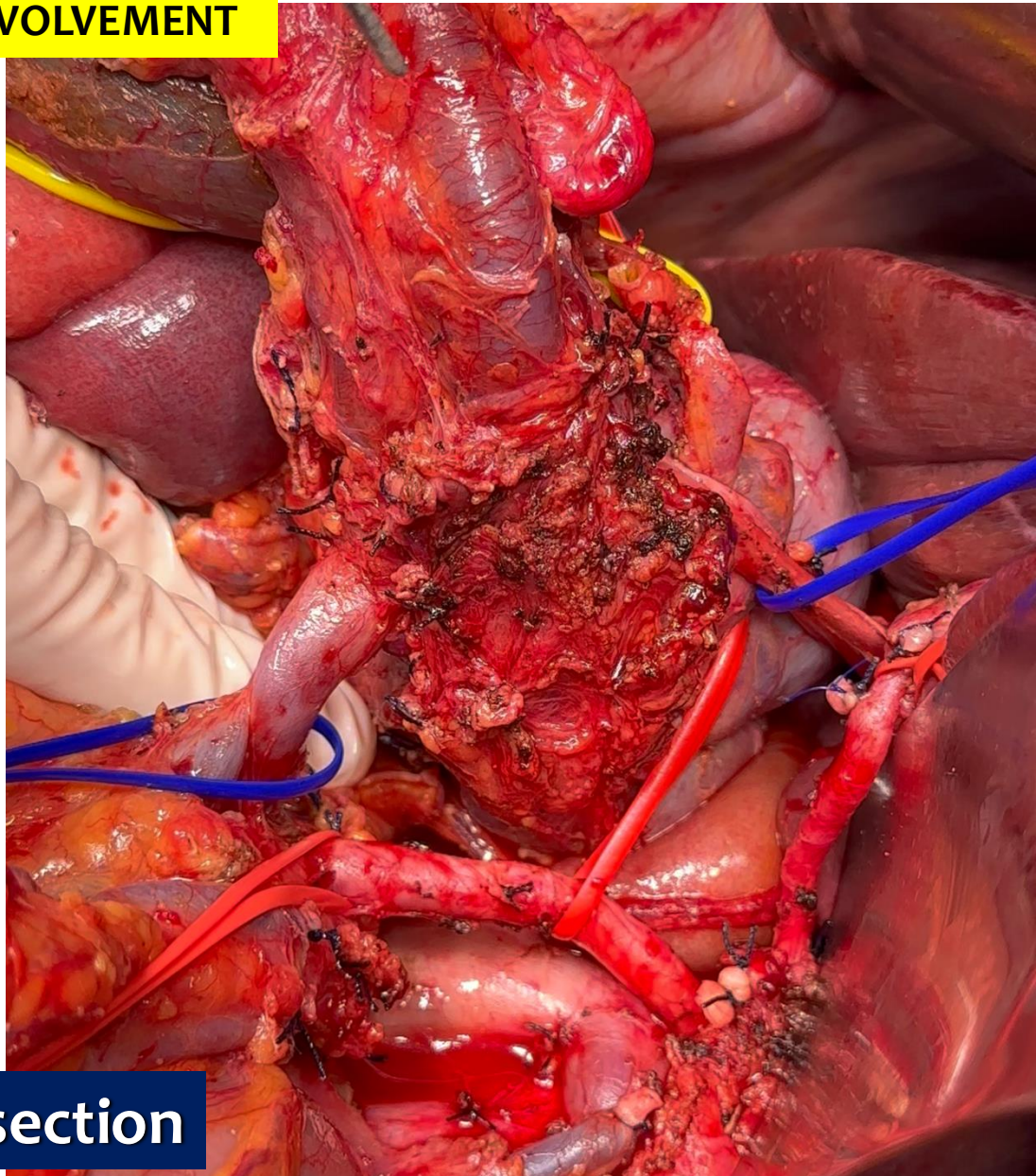
Vascular resection

## VASCULAR INVOLVEMENT



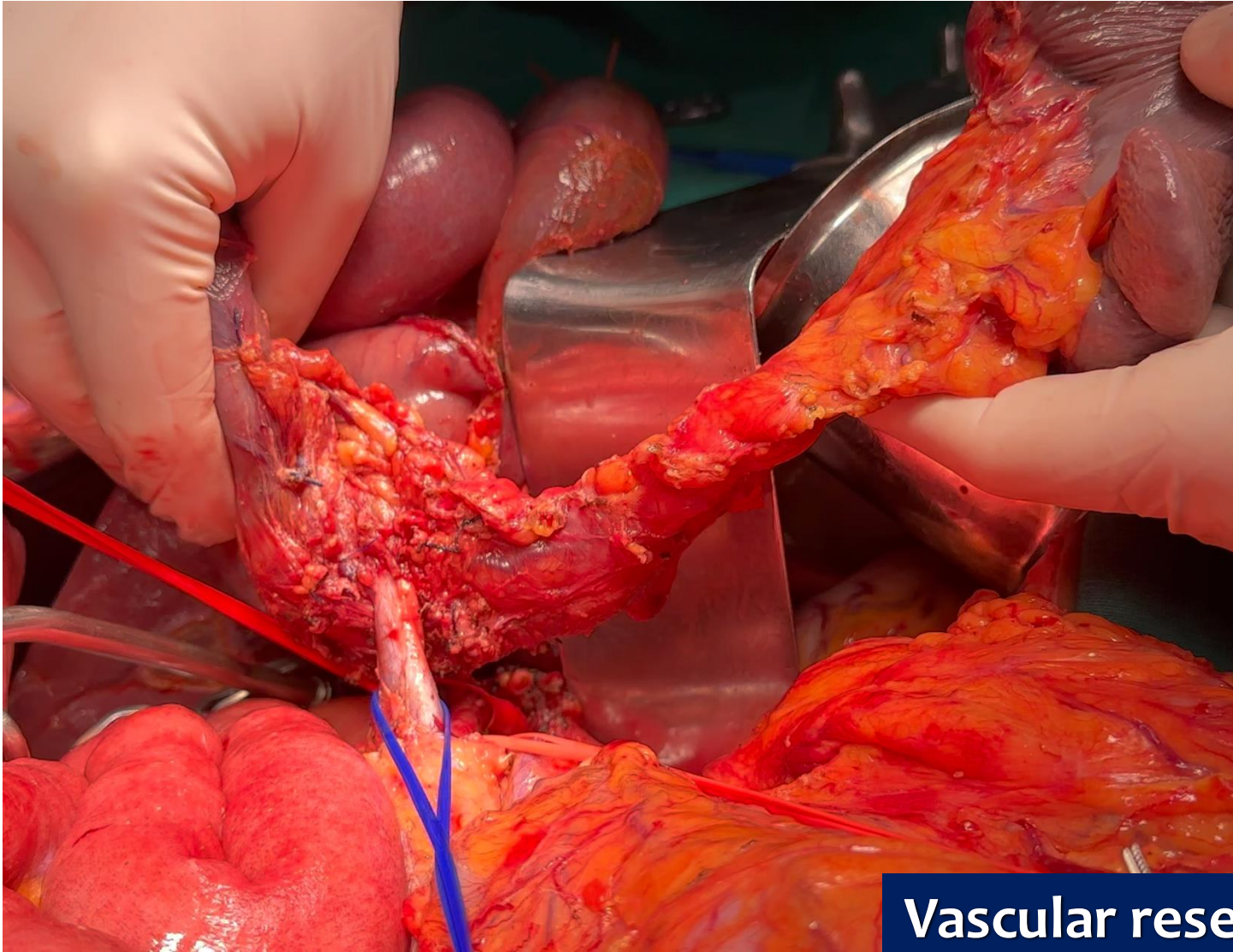
Vascular resection

## VASCULAR INVOLVEMENT



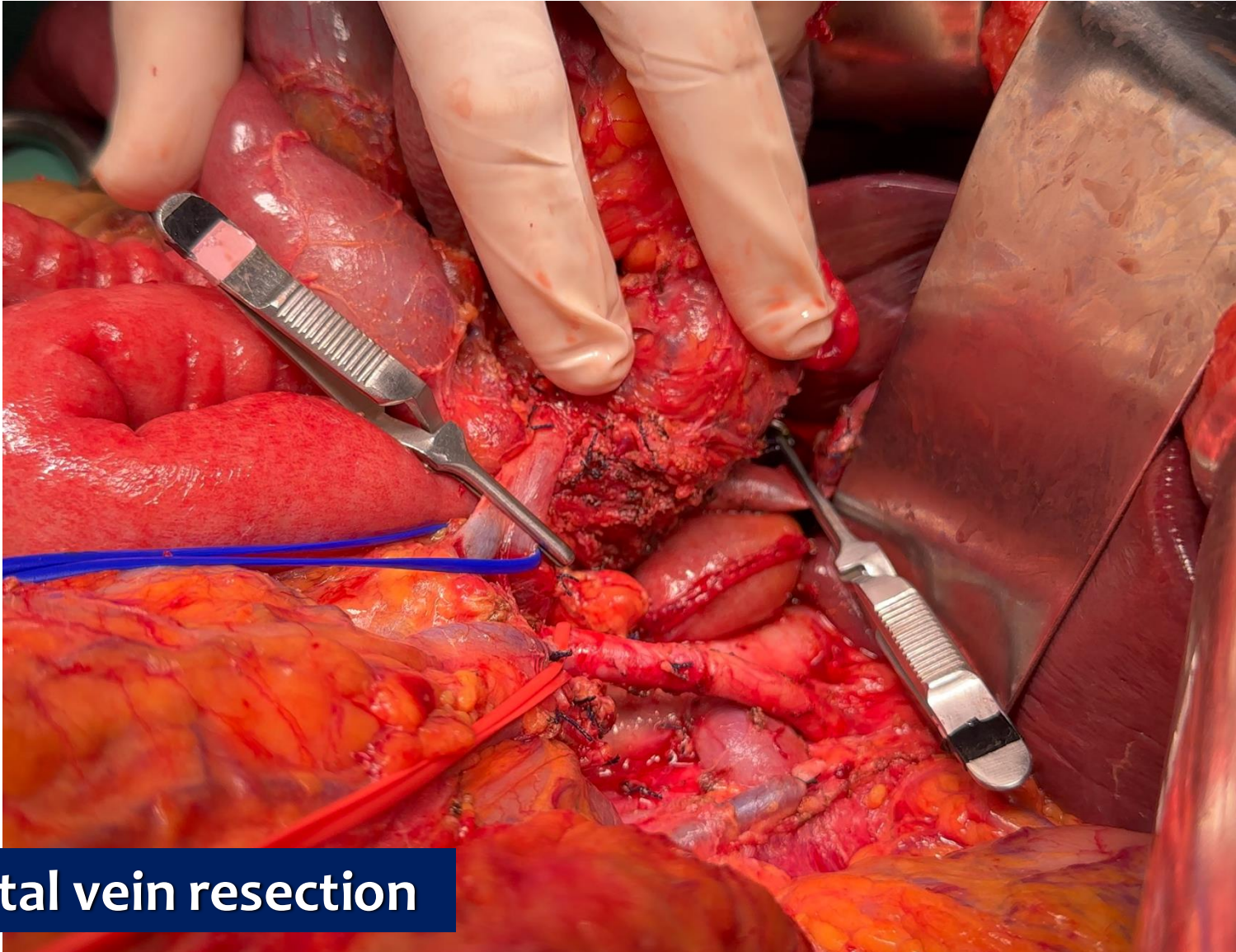
Vascular resection

## VASCULAR INVOLVEMENT



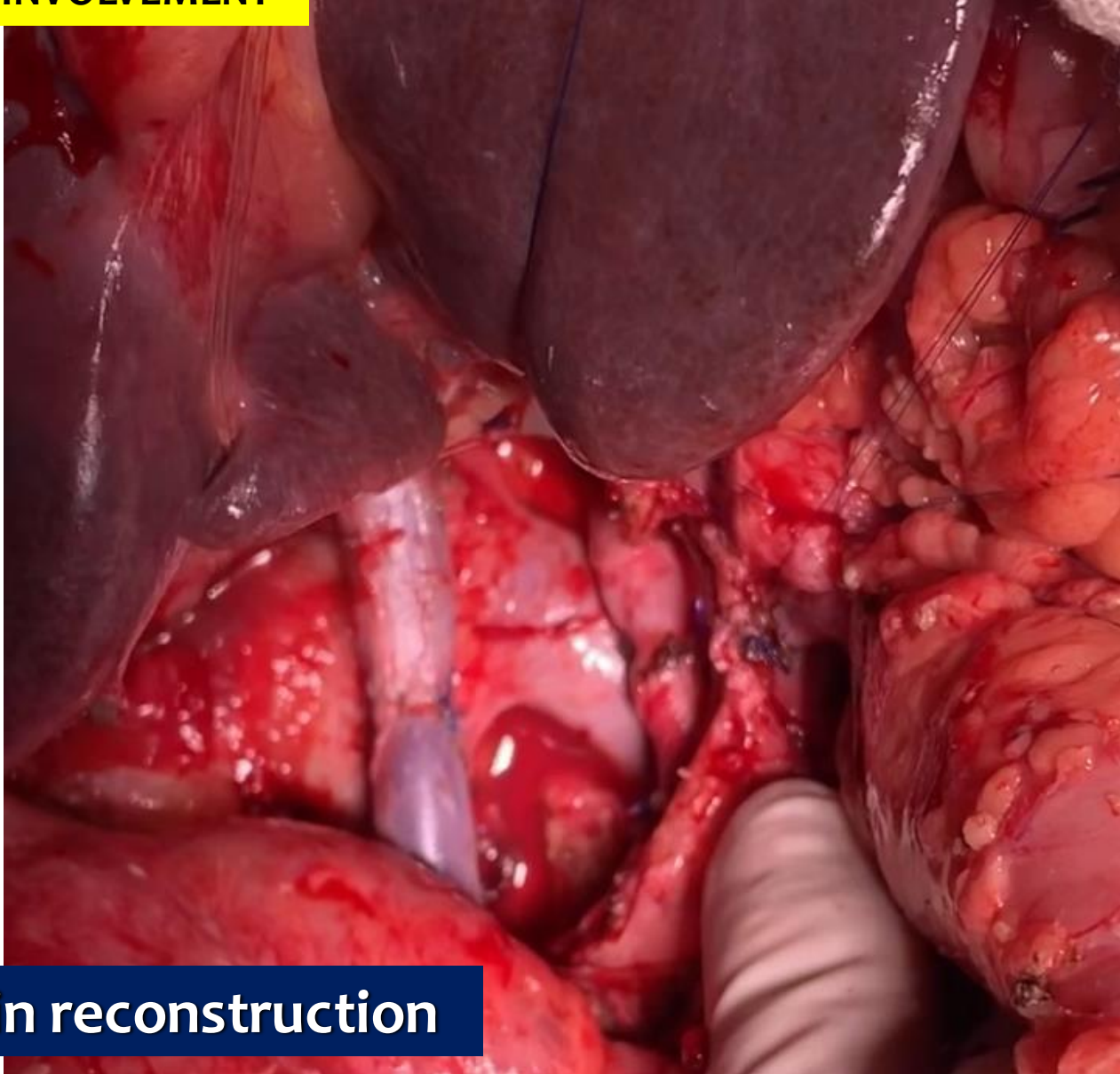
**Vascular resection**

## VASCULAR INVOLVEMENT



Portal vein resection

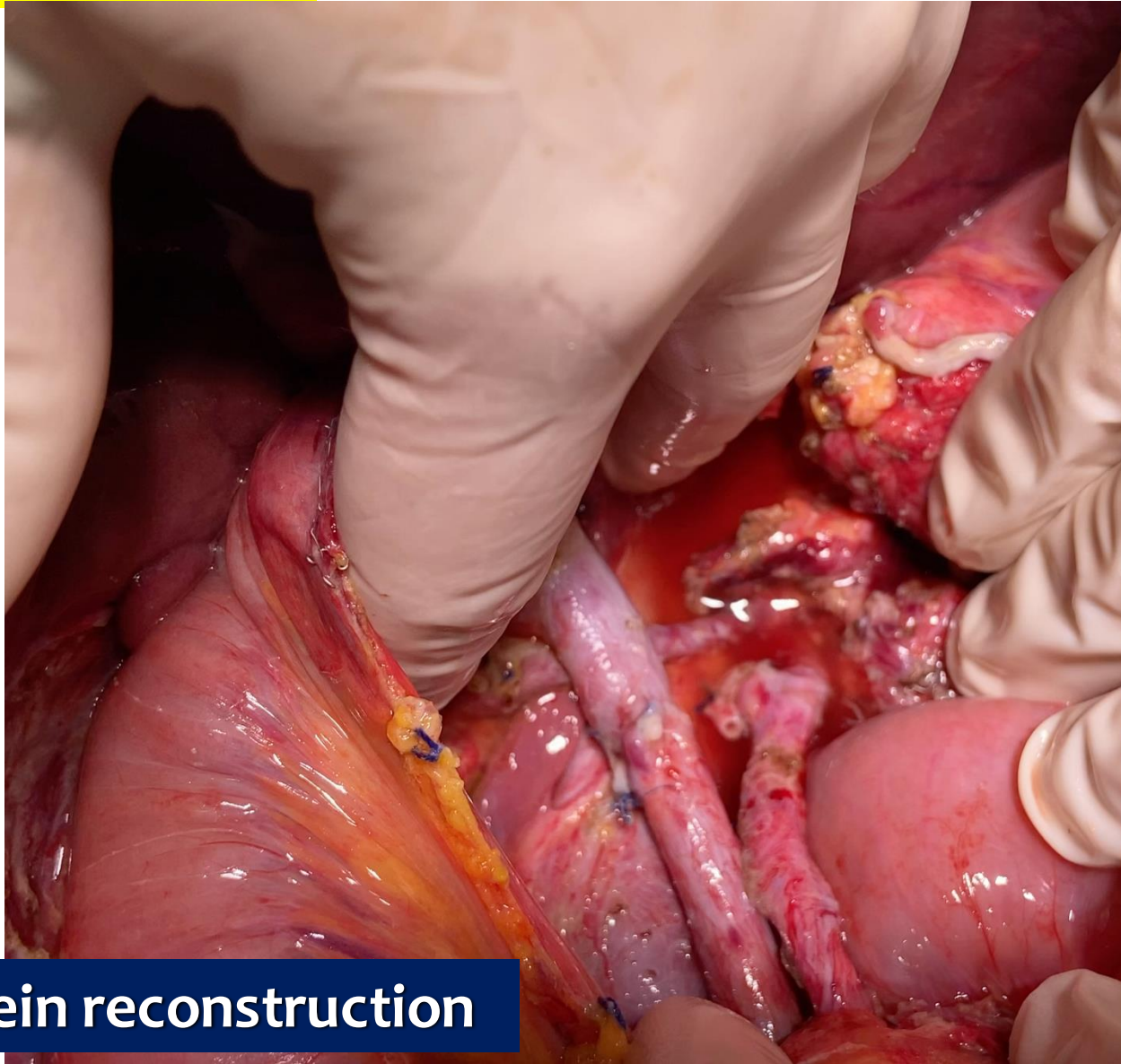
## VASCULAR INVOLVEMENT



Portal vein reconstruction

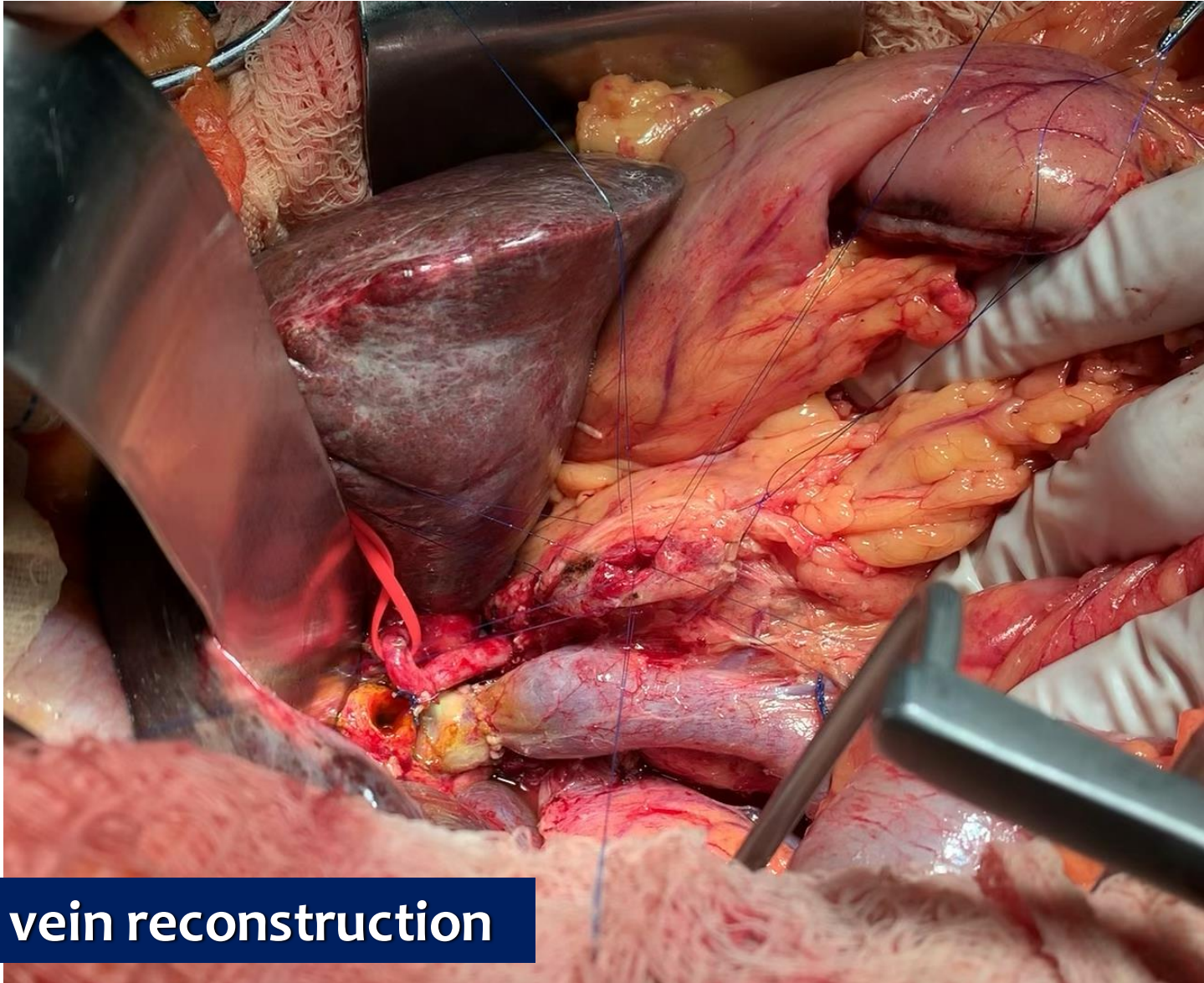


## VASCULAR INVOLVEMENT



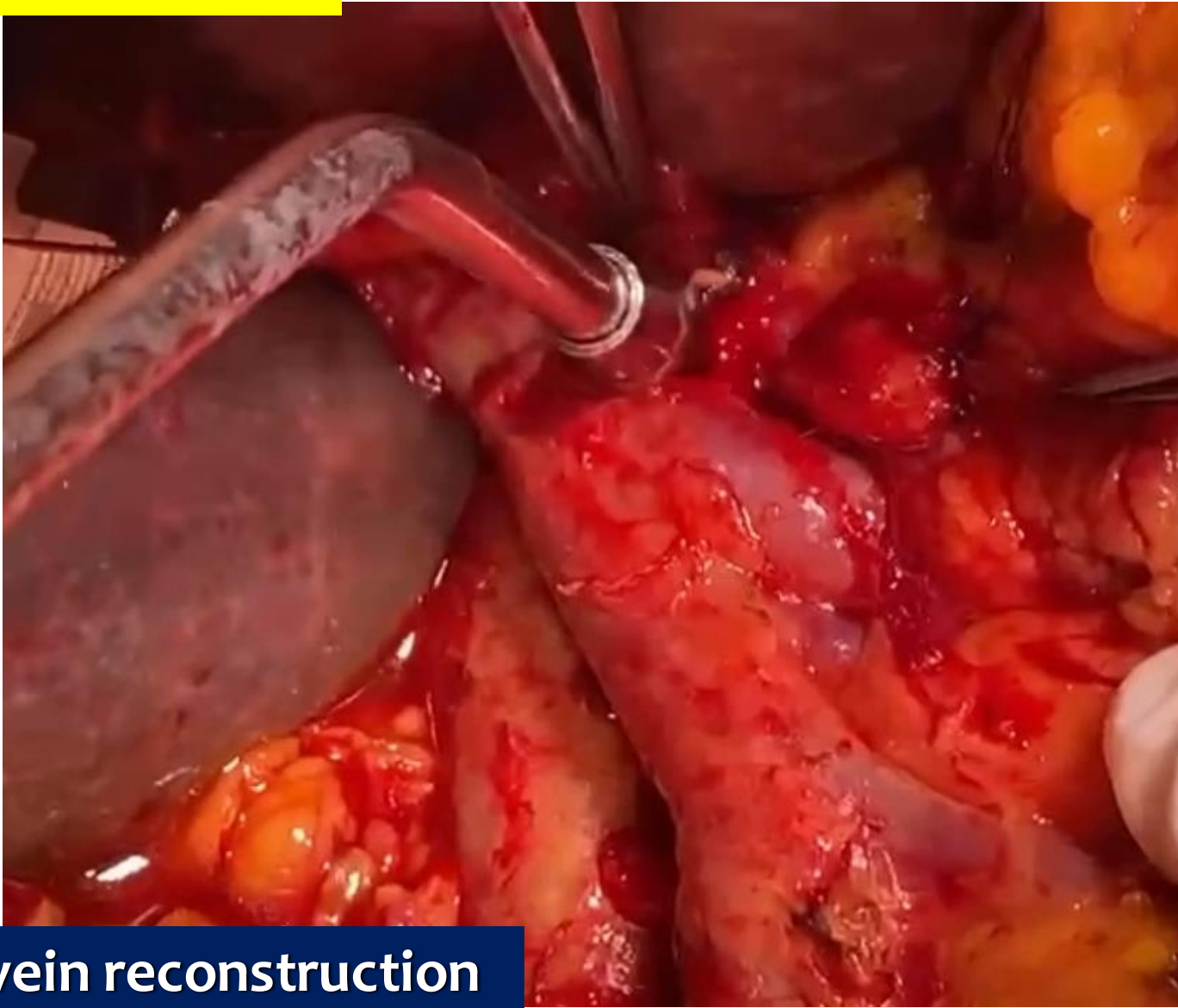
**Portal vein reconstruction**

## VASCULAR INVOLVEMENT



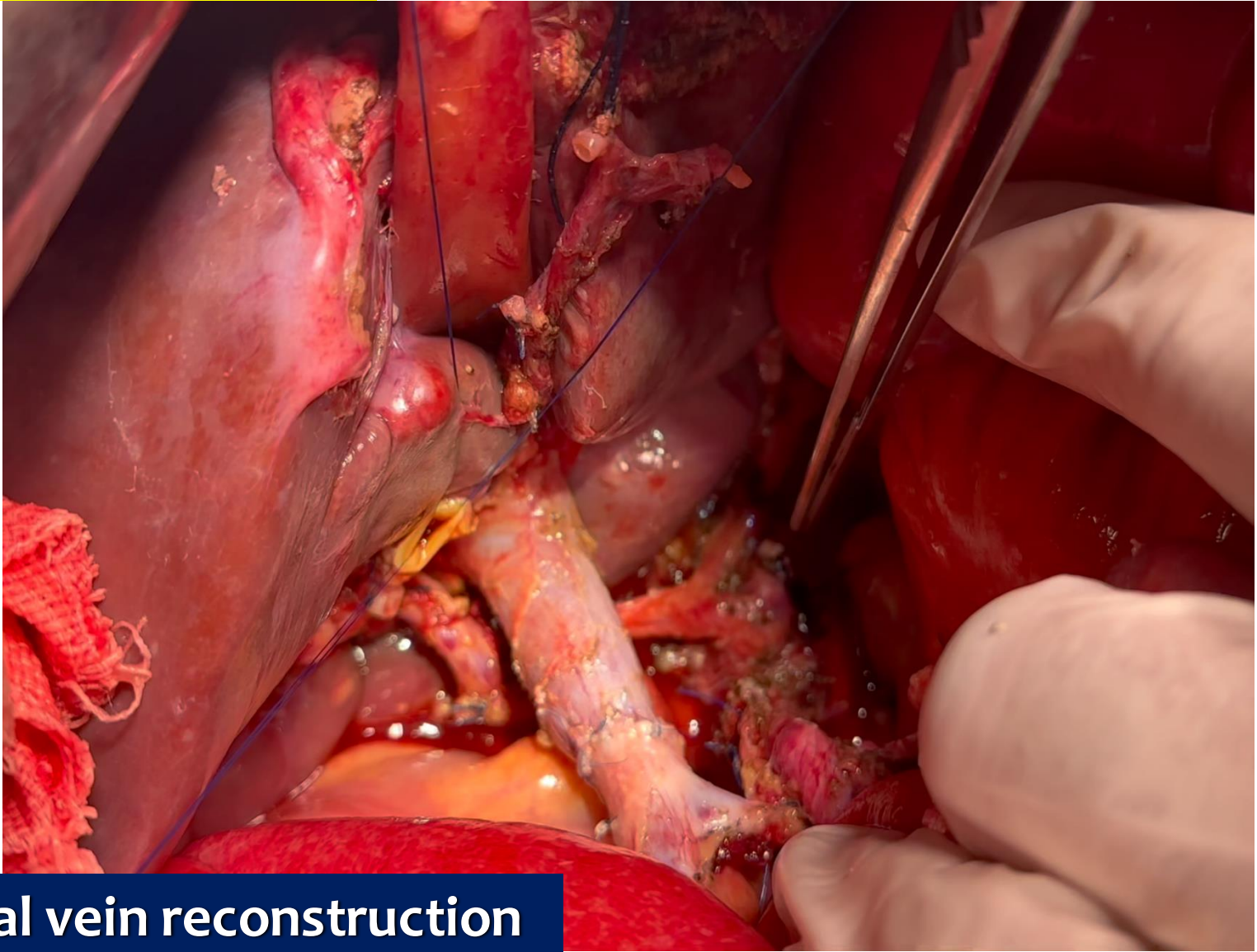
Portal vein reconstruction

## VASCULAR INVOLVEMENT



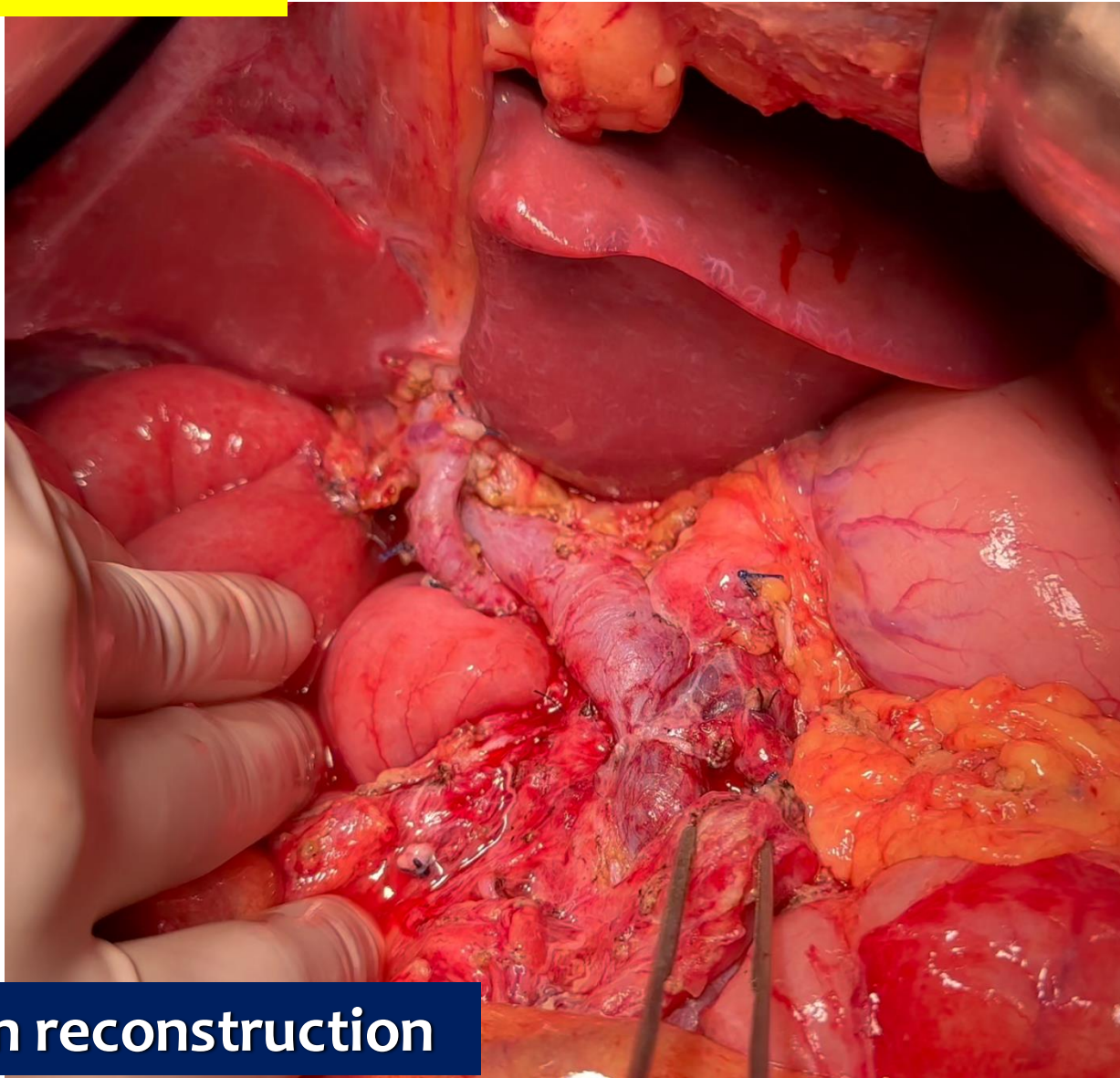
Portal vein reconstruction

## VASCULAR INVOLVEMENT



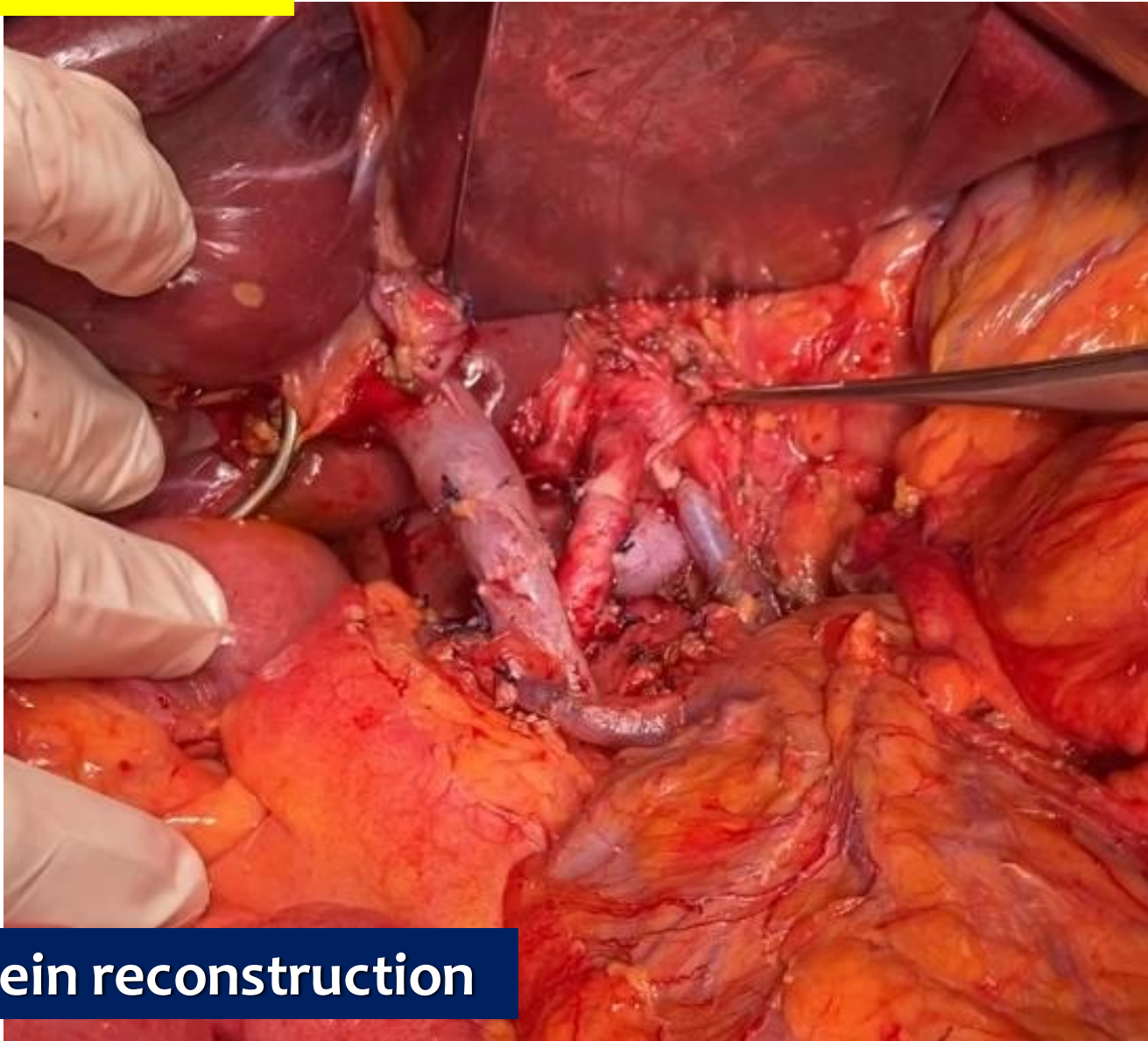
Portal vein reconstruction

## VASCULAR INVOLVEMENT



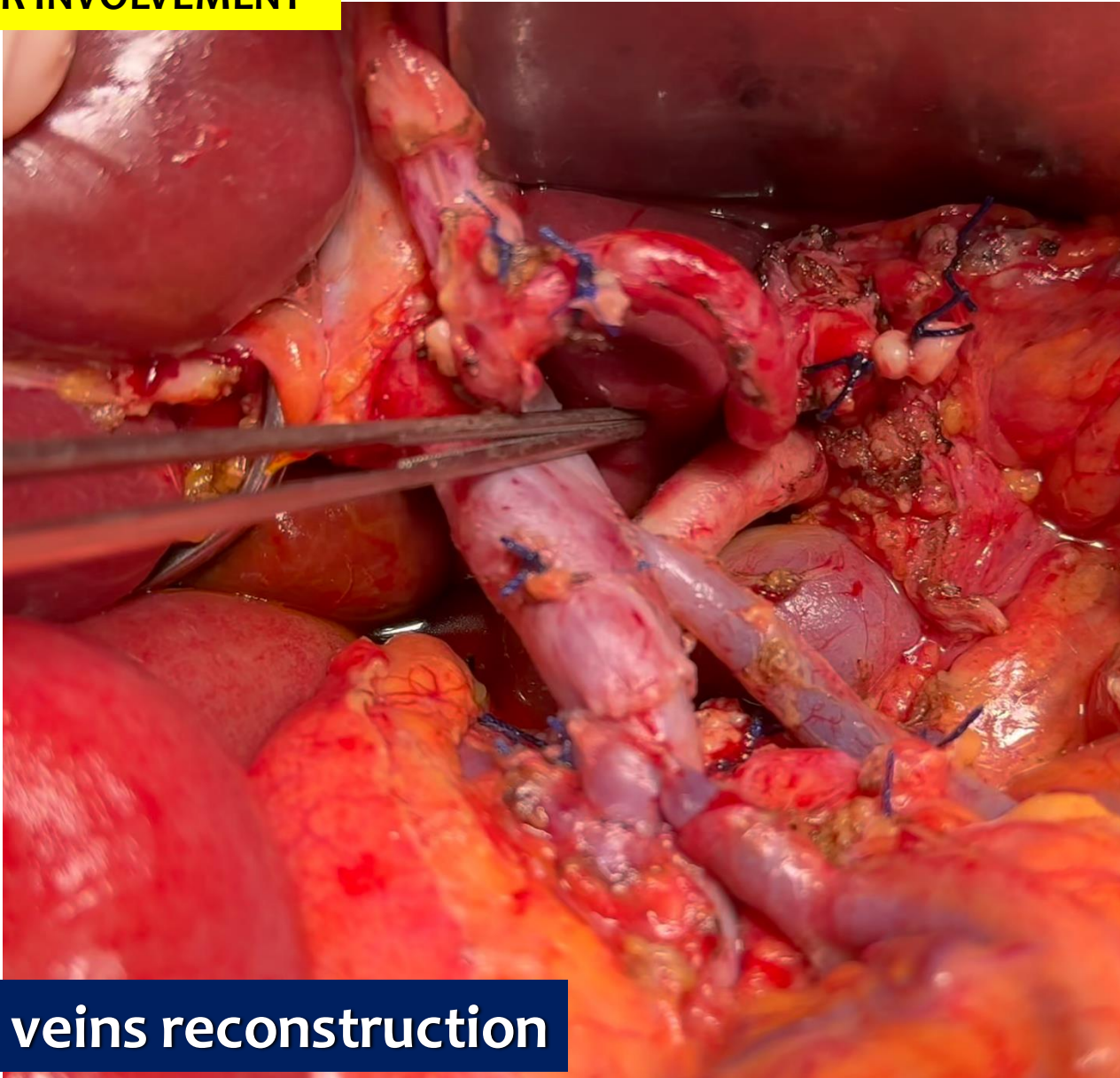
Portal vein reconstruction

## VASCULAR INVOLVEMENT



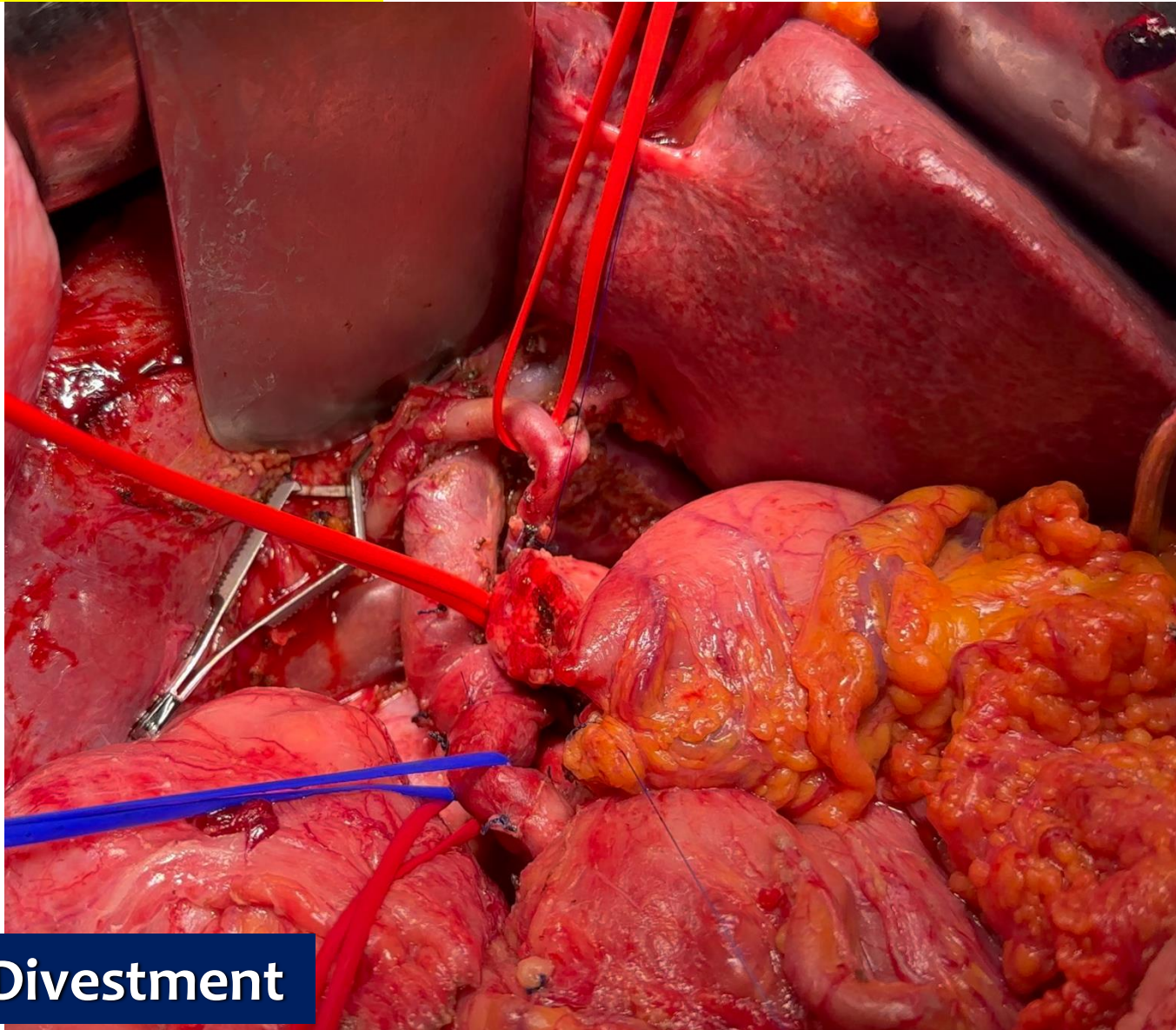
## Portal vein reconstruction

## VASCULAR INVOLVEMENT



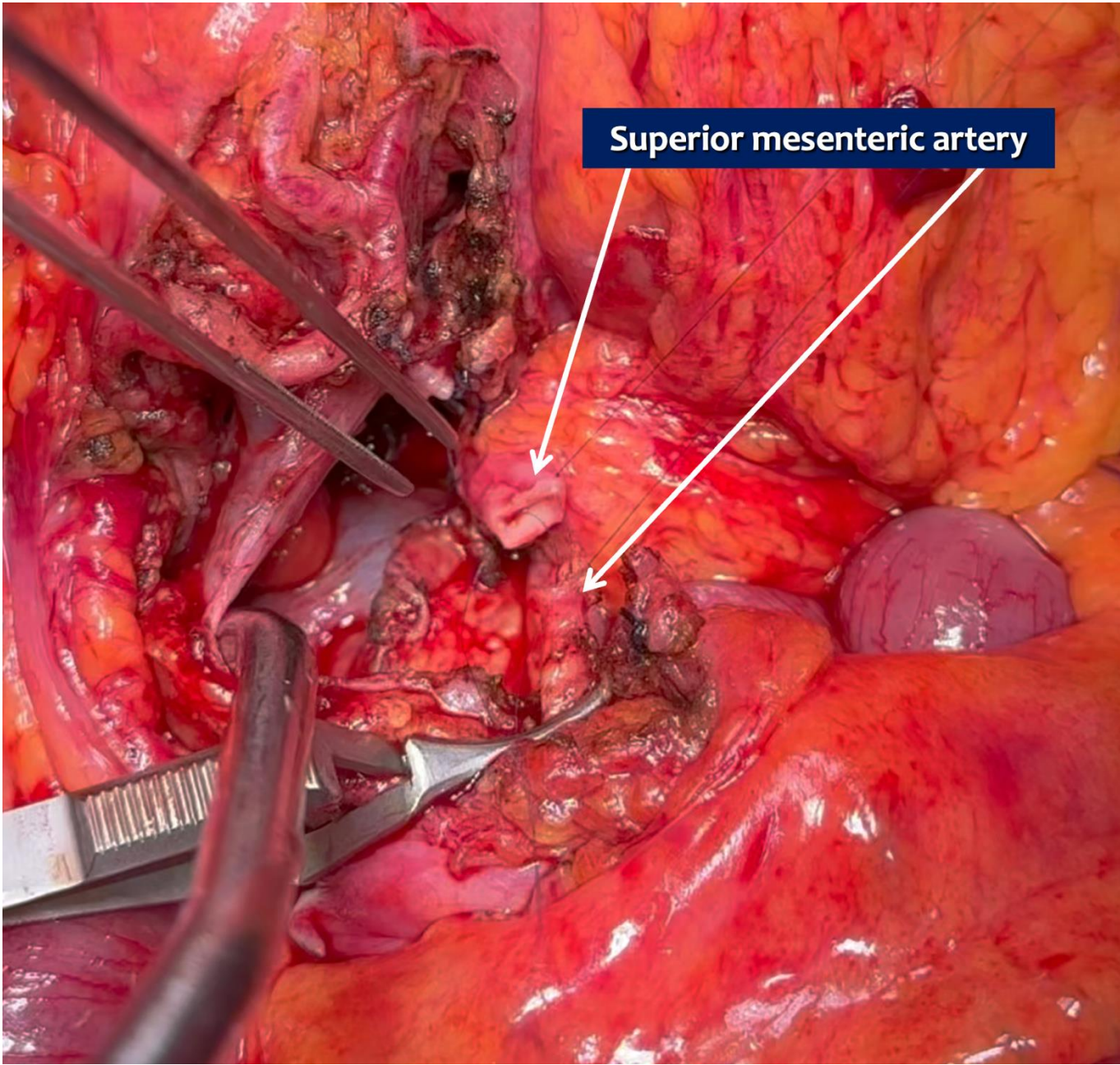
**Jejunal veins reconstruction**

# VASCULAR INVOLVEMENT

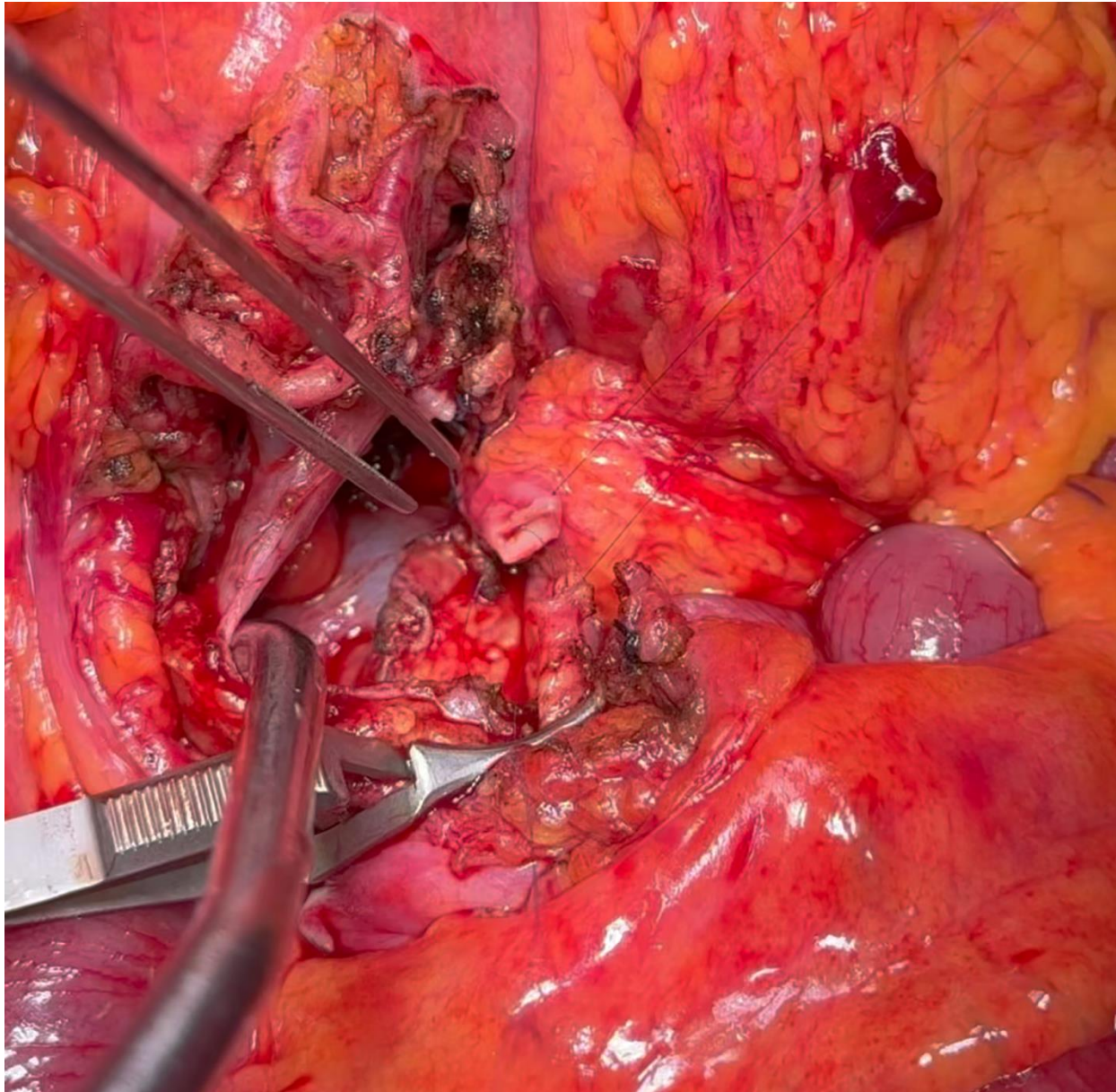


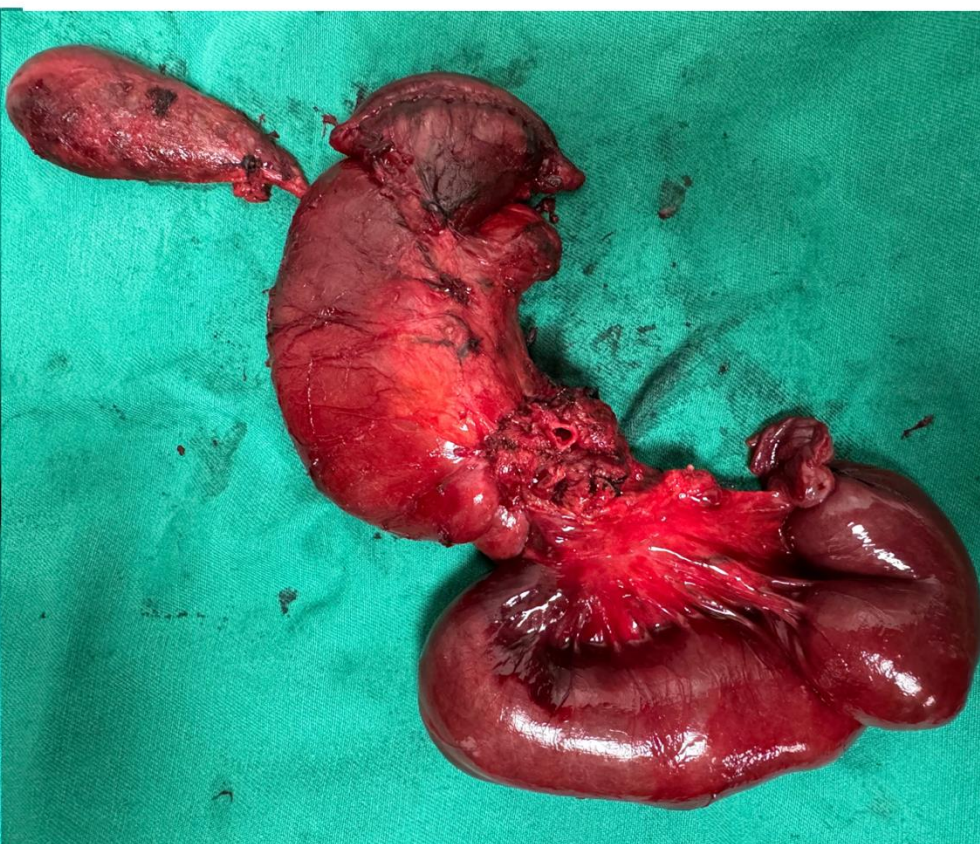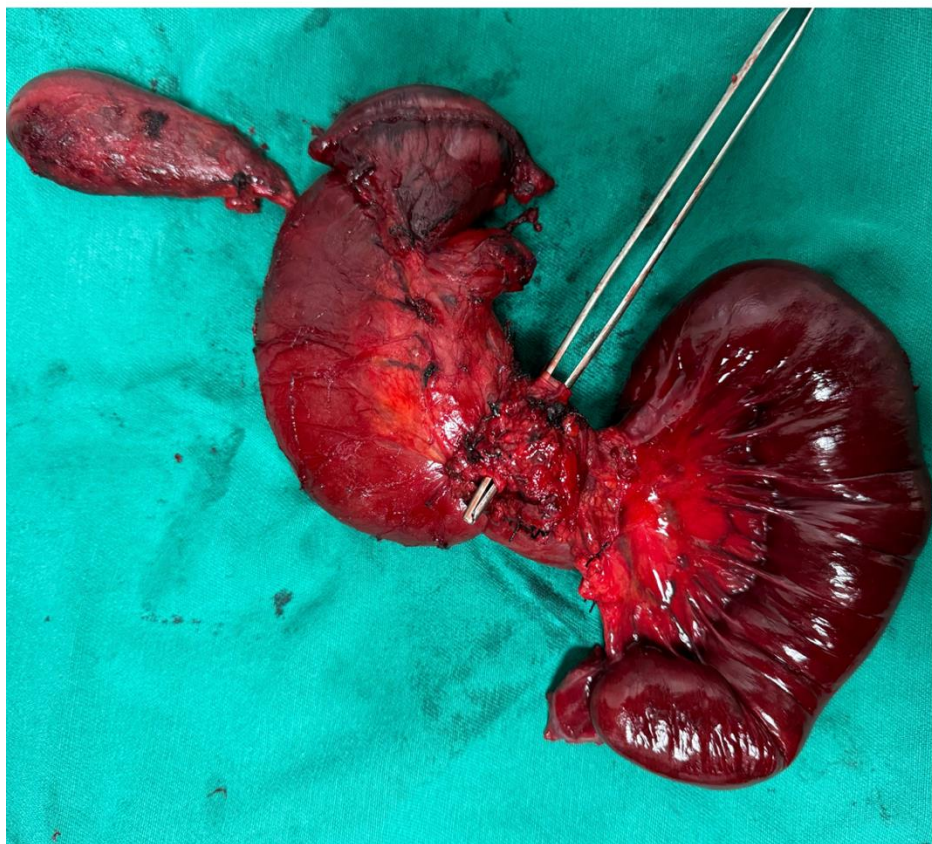**SMA Divestment**





Superior mesenteric artery







Lençóis Maranhenses

Thanks!



[www.drorlandotorres.com.br](http://www.drorlandotorres.com.br)

 [orlandotorres@gastrocirurgia](https://www.instagram.com/orlandotorres@gastrocirurgia)